# Caso clínico II: Paciente con sospecha de TVP en una pierna en la que ya había presentado un episodio anterior

Servicio de Angiología, Cirugía Vascular y Endovascular
Hospital Virgen de la Salud
Toledo

# DEFINICIÓN DE TVPR

Recurrencia en contigüidad

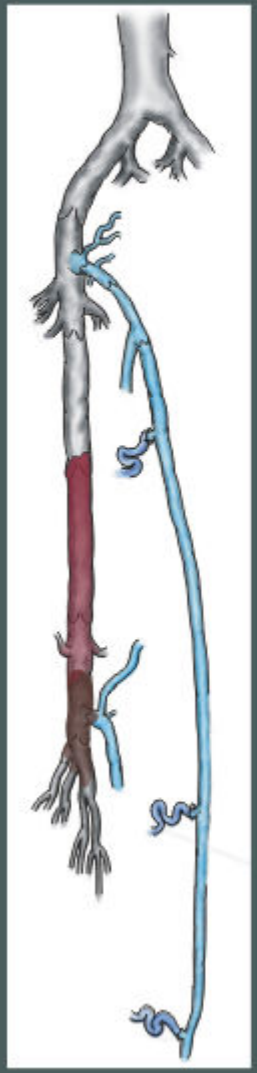

Recurrencia a distancia

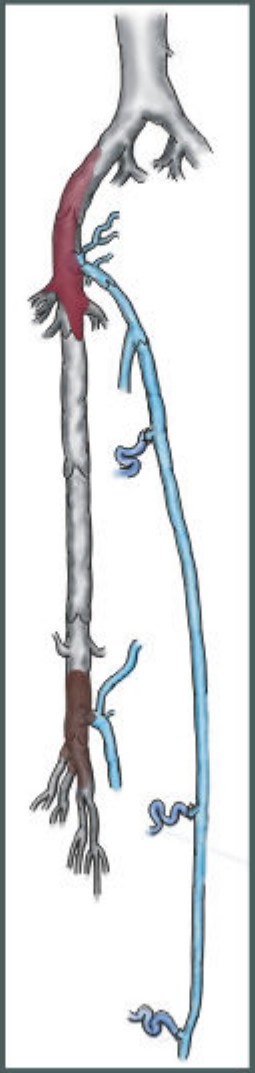

Recurrencia "in situ"

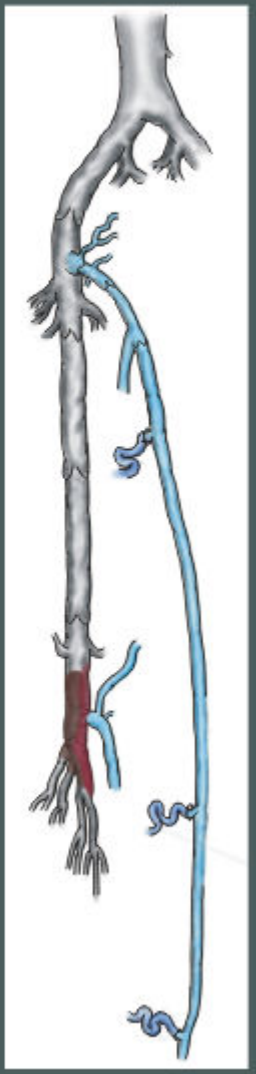

# EVOLUCIÓN DURANTE EL PRIMER AÑO TRAS UNA TVP

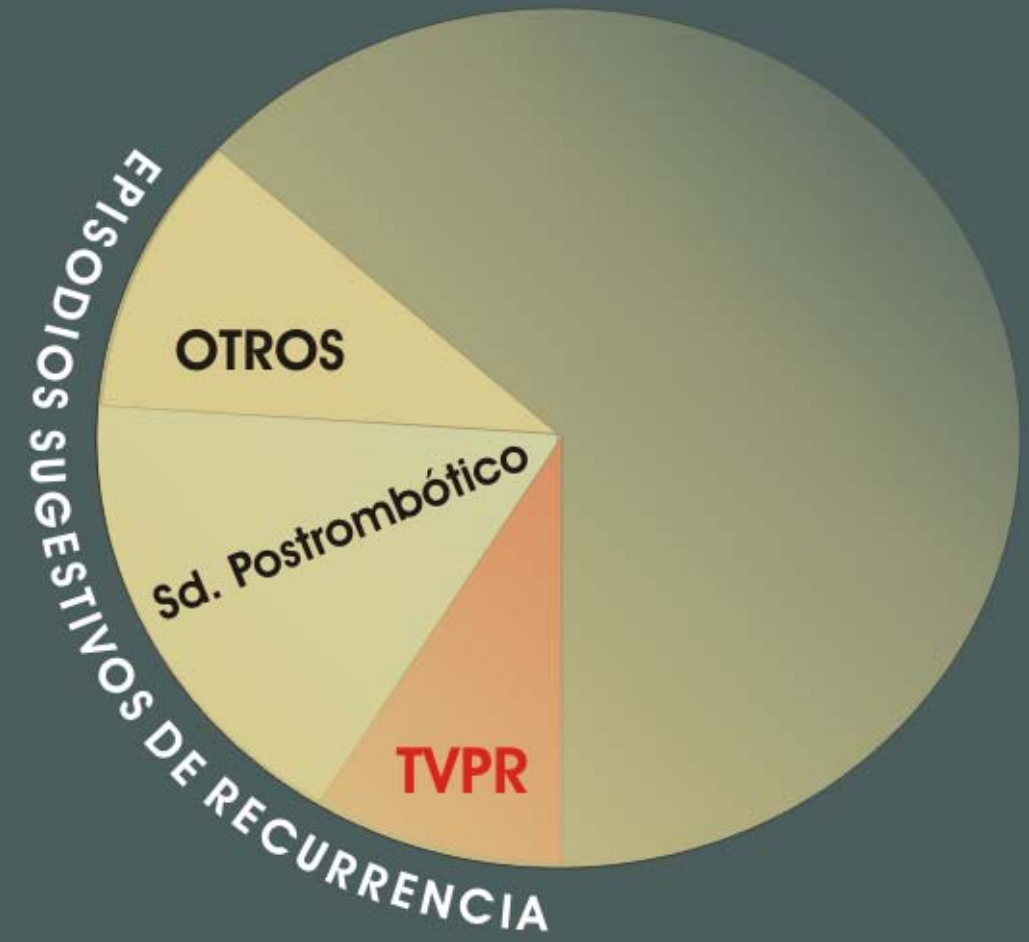

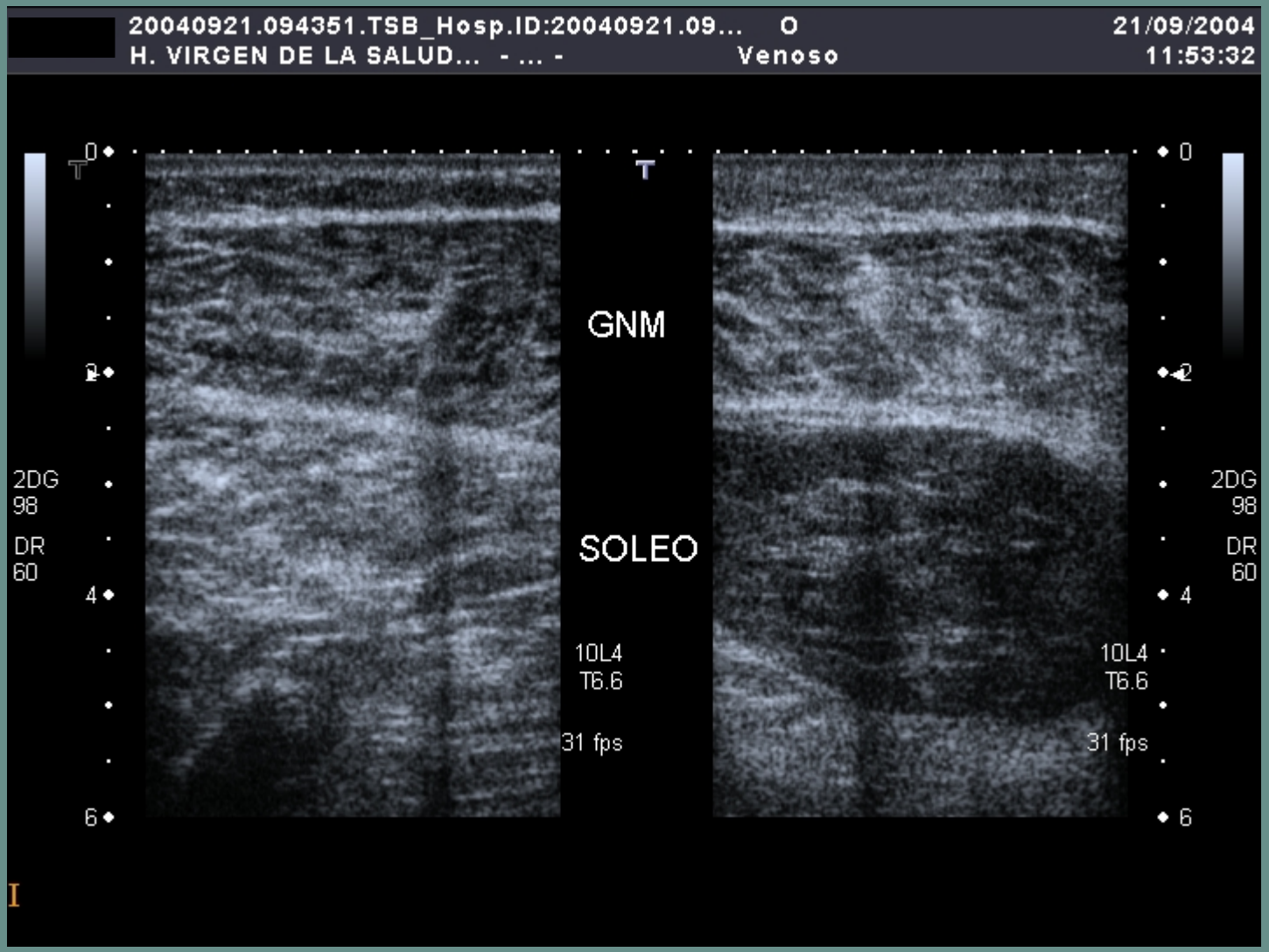
20040921.094351.TSB_Hosp.ID:20040921.09... O
H. VIRGEN DE LA SALUD... - ... -
Venoso
21/09/2004
11:53:32
GNM
SOLEO
2DG
98
DR
60
10L4
T6.6
31 fps
2DG
98
DR
60
10L4
T6.6
31 fps

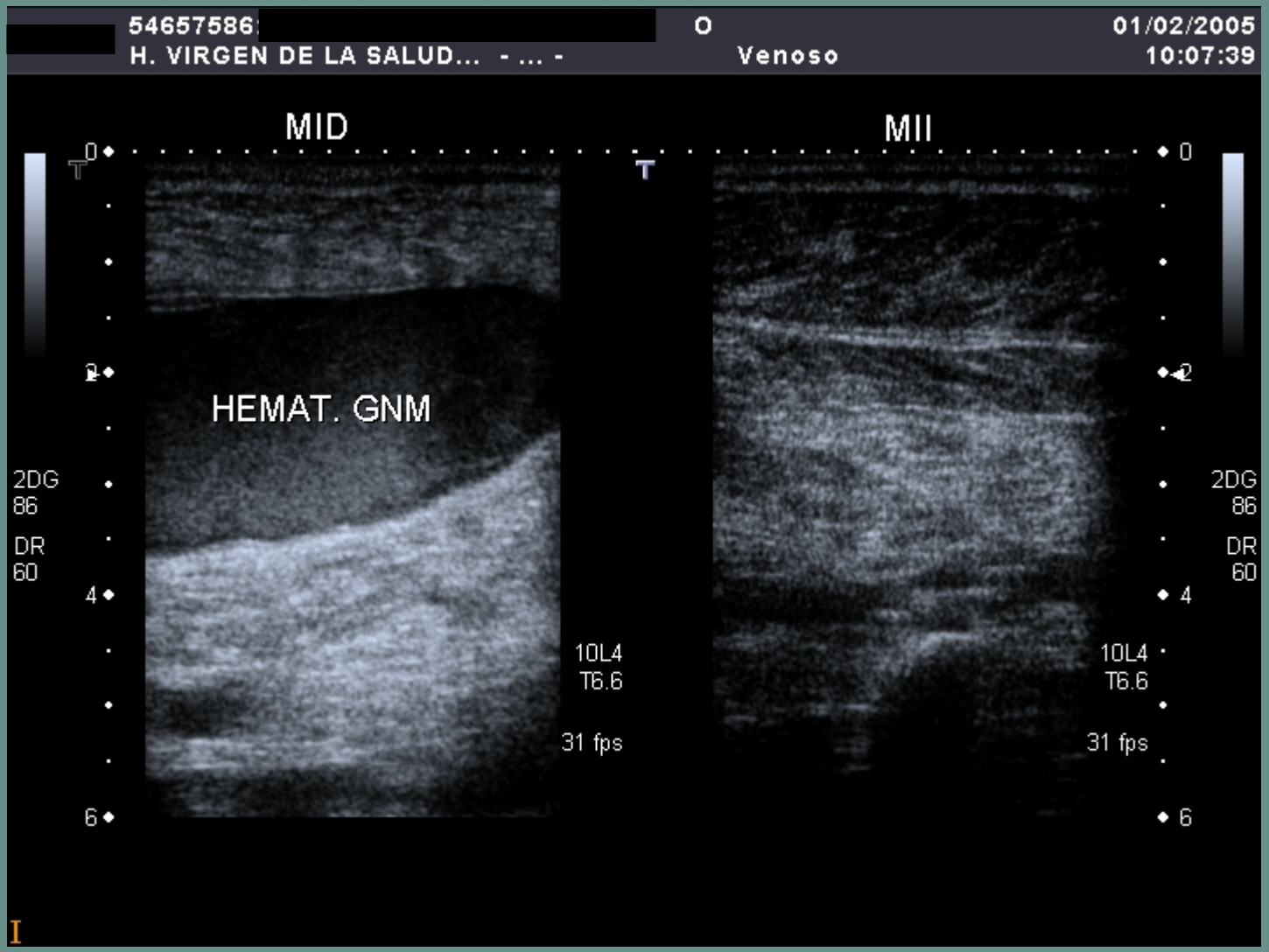
54657586
H. VIRGEN DE LA SALUD... - ... -
O
Venoso
01/02/2005
10:07:39
MID
MII
HEMAT. GNM
2DG
86
DR
60
10L4
T6.6
31 fps
0
2
4
6

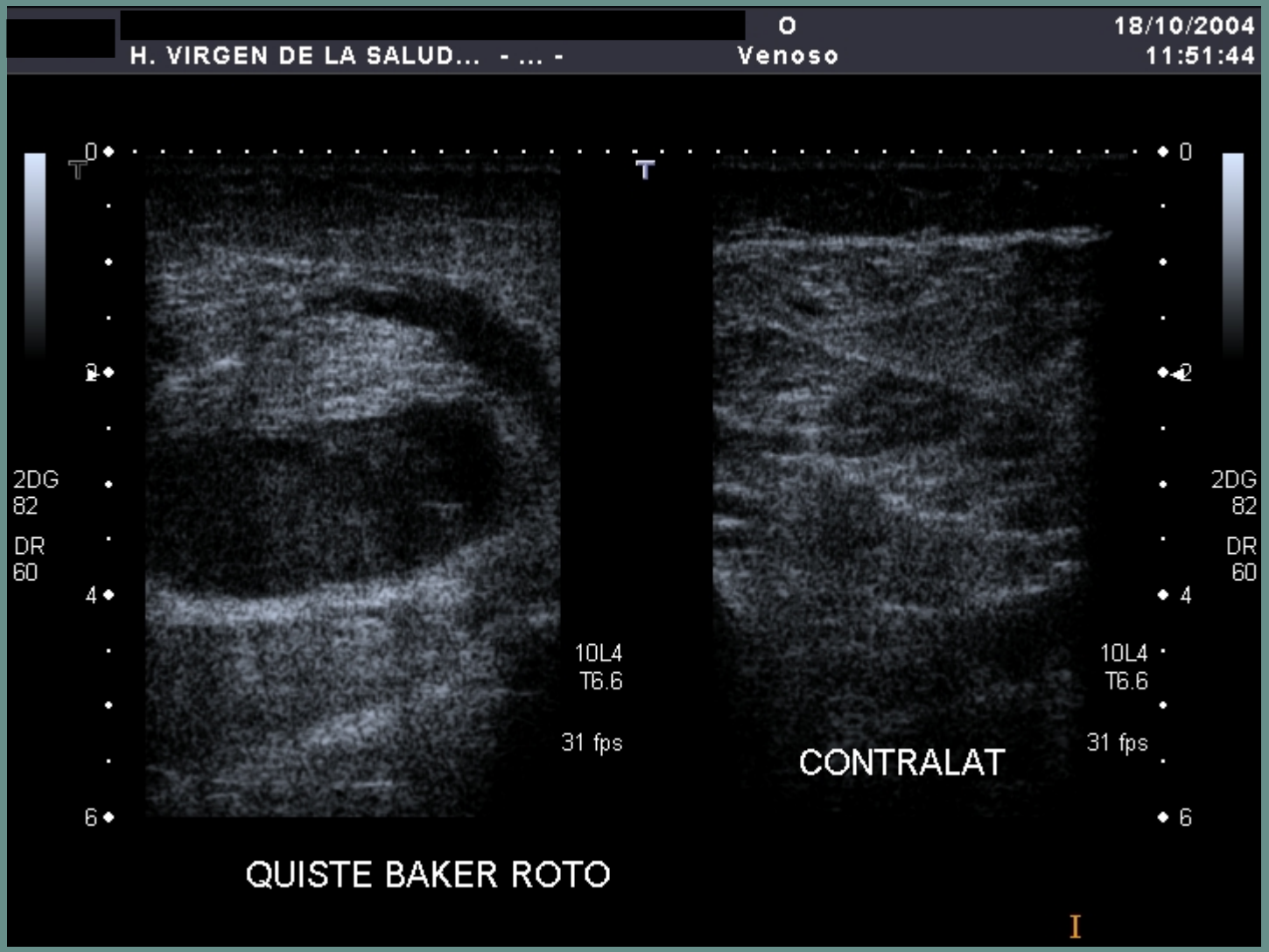
H. VIRGEN DE LA SALUD... - ... -
O
Venoso
18/10/2004
11:51:44
2DG
82
DR
60
10L4
T6.6
31 fps
QUISTE BAKER ROTO
CONTRALAT

Varón - 59 años

## Antecedentes personales

No alergias medicamentosas
Fumador de 3,5 paquetes al día
Bebedor importante en fin de semana (6-7 l. Cerveza/día)
Hiperuricemia asintomática
Infarto hemiprotuberancia izquierda hace 9 meses
HTA. No diabetes ni dislipemias

## Clínica

Dolor sóleo-gemelar progresivo
Aumento de diámetro
"Empastamiento" muscular

## Pruebas complementarias

Analítica simple
Eco-doppler color

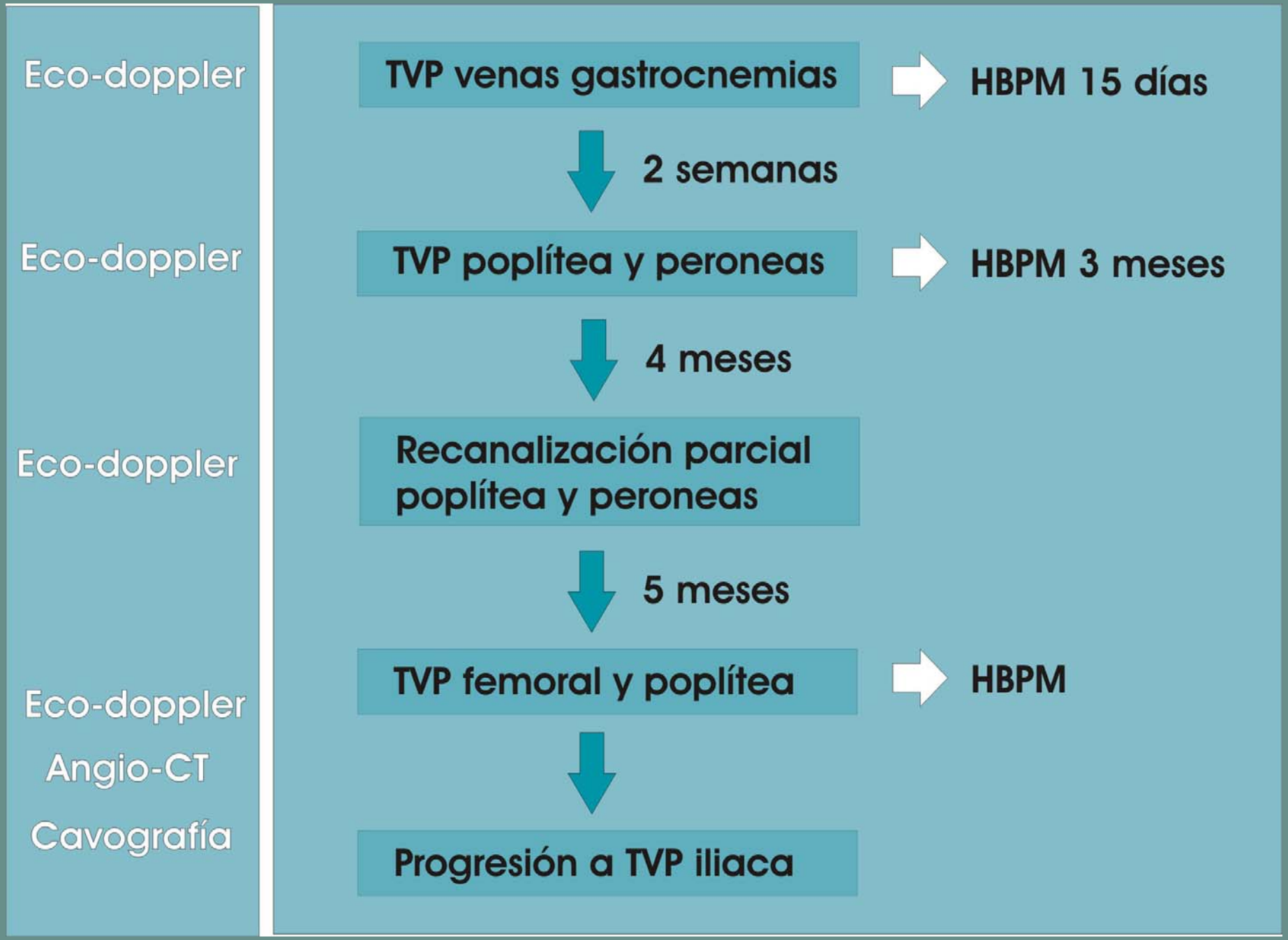
Eco-doppler
TVP venas gastrocnemias
HBPM 15 días
2 semanas
Eco-doppler
TVP poplítea y peroneas
HBPM 3 meses
4 meses
Eco-doppler
Recanalización parcial poplítea y peroneas
5 meses
Eco-doppler
Angio-CT
Cavografía
TVP femoral y poplítea
HBPM
Progresión a TVP iliaca

# DIFERENCIAS ENTRE TESTS

| Consideraciones | Eco-doppler | Dímero-D | RMN | CT | Flebografía |
|---|---|---|---|---|---|
| Invasividad | 🟢 | 🟢 | 🟢 | 🟢 | 🔴 |
| Contraste | 🟢 | 🟢 | 🟢 | 🔴 | 🔴 |
| Radiación | 🟢 | 🟢 | 🟢 | 🔴 | 🔴 |
| Coste | 🟢 | 🟢 | 🔴 | 🔴 | 🔴 |
| Subjetividad | 🔴 | 🟢 | 🟢 | 🟢 | 🟢 |
| Repetibilidad | 🟢 | 🟢 | 🔴 | 🔴 | 🔴 |
| Disponibilidad | 🟢 | 🔴 | 🔴 | 🟢 | 🔴 |
| V. inter-obser. | 🔴 | 🟢 | 🟢 | 🟢 | 🟢 |
| V. intra-obser. | 🟢 | 🟢 | 🟢 | 🟢 | 🟢 |

# ECO-DOPPLER. CRITERIOS DE TVP

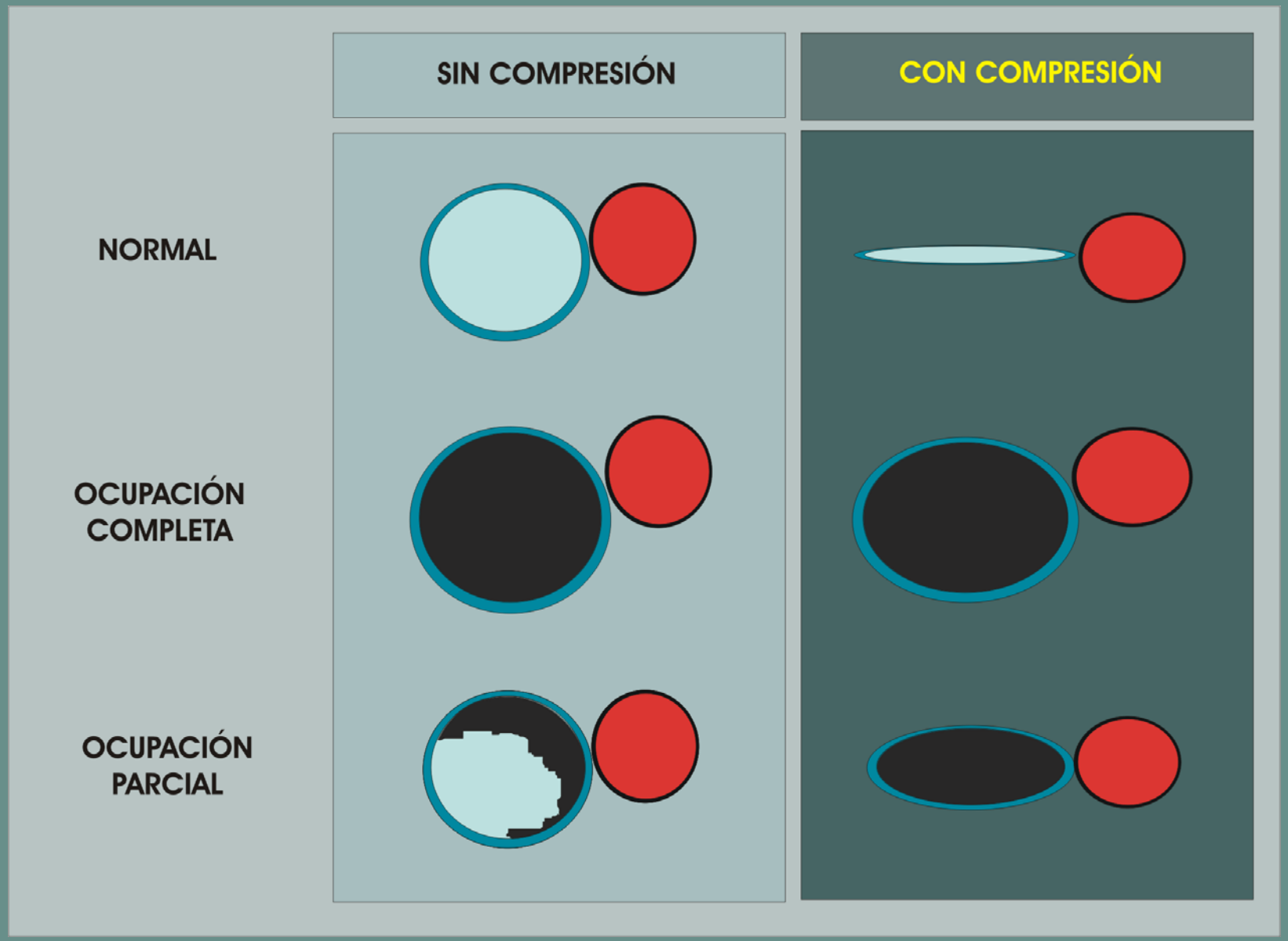

# FIABILIDAD DE LOS TESTS POR SECTORES

| TVP INICIAL | Eco-doppler | Dímero-D | RMN | CT | Flebografía |
|---|---|---|---|---|---|
| **Sensibilidad** | | | | | |
| Ilio-cava | 🔴 | 🟢 | 🟢 | 🟢 | 🟢 |
| Fémoro-poplíteo | 🟢 | 🟢 | 🟢 | 🟢 | 🟢 |
| Distal | 🔴 | 🟢 | 🔴 | 🔴 | 🟢 |
| **Especificidad** | | | | | |
| Ilio-cava | 🟢 | 🔴 | 🟢 | 🟢 | 🟢 |
| Fémoro-poplíteo | 🟢 | 🔴 | 🟢 | 🟢 | 🟢 |
| Distal | 🟢 | 🔴 | 🔴 | 🔴 | 🟢 |

# FIABILIDAD DE LOS TESTS POR SECTORES

| | | | | |
|---|---|---|---|---|
| Baja Sensibilidad | ➡ | Aumento de falsos negativos | ➡ | Riesgo de TEP |
| Baja Especificidad | ➡ | Aumento de falsos positivos | ➡ | Riesgo de sangrado |

| TVP RECURRENTE | Eco-doppler | Dímero-D | RMN | CT | Flebografía |
|---|---|---|---|---|---|
| **Sensibilidad** | | | | | |
| Ilio-cava | 🔴 | 🟢 | 🟢 | 🟢 | 🟢 |
| Fémoro-poplíteo | 🟢 | 🟢 | 🟢 | 🟢 | 🟢 |
| Distal | 🔴 | 🟢 | 🔴 | 🔴 | 🟢 |
| **Especificidad** | | | | | |
| Ilio-cava | 🔴 | 🔴 | 🔴 | 🔴 | 🔴 |
| Fémoro-poplíteo | 🔴 | 🔴 | 🔴 | 🔴 | 🔴 |
| Distal | 🔴 | 🔴 | 🔴 | 🔴 | 🔴 |

## FALSOS POSITIVOS

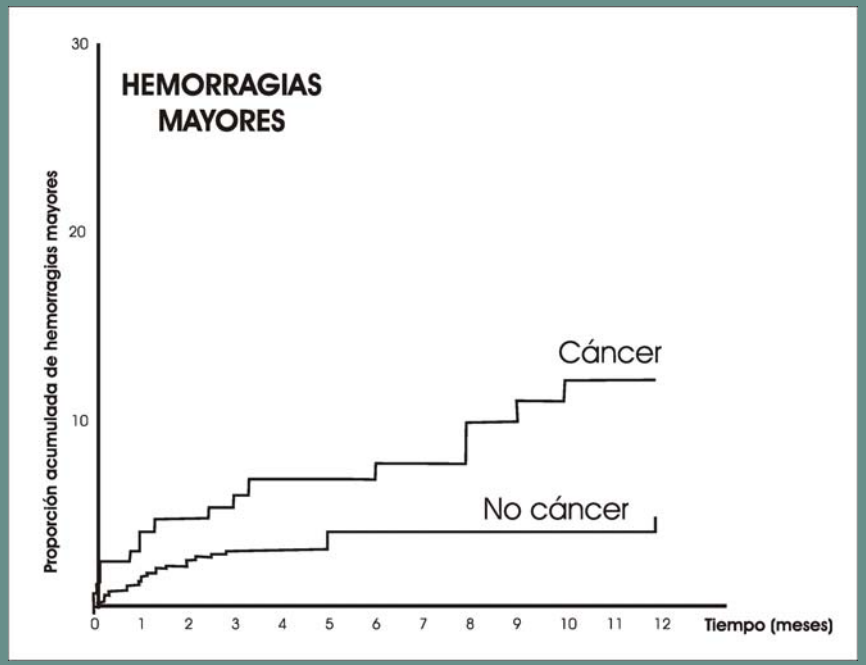


## FALSOS NEGATIVOS

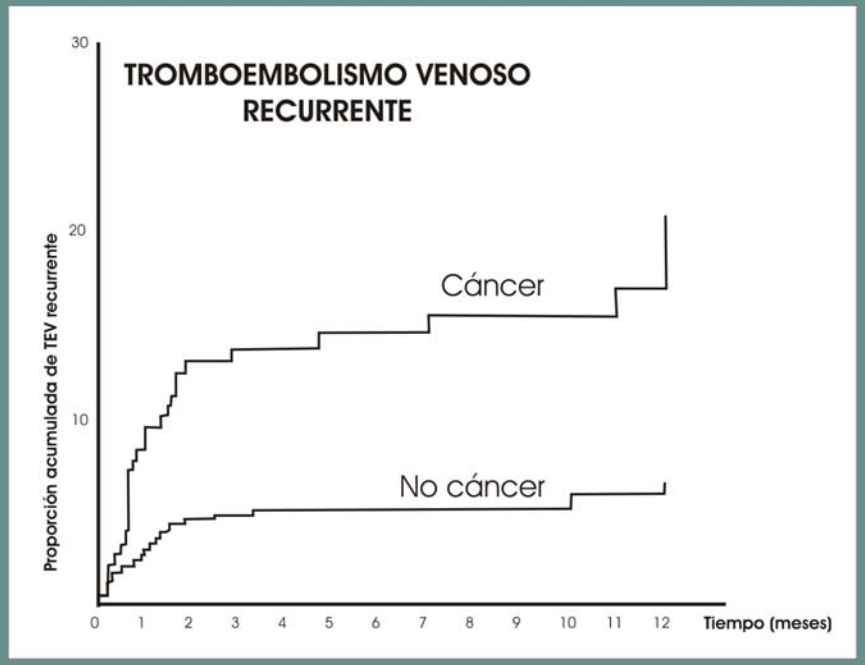


Prandoni P, Lensing AWA, Piccioli A, Bernardi E, Simioni P, Girolami B, Marchiori A, Sabbion P, Prins MH, Noventa F, Girolami A. Recurrent venous thromboembolism and bleeding complications during anticoagulant treatment in patients with cancer and venous thrombosis.
Blood 2002;100:3484-3488.

# MEDIDA DEL DIÁMETRO DE REFERENCIA

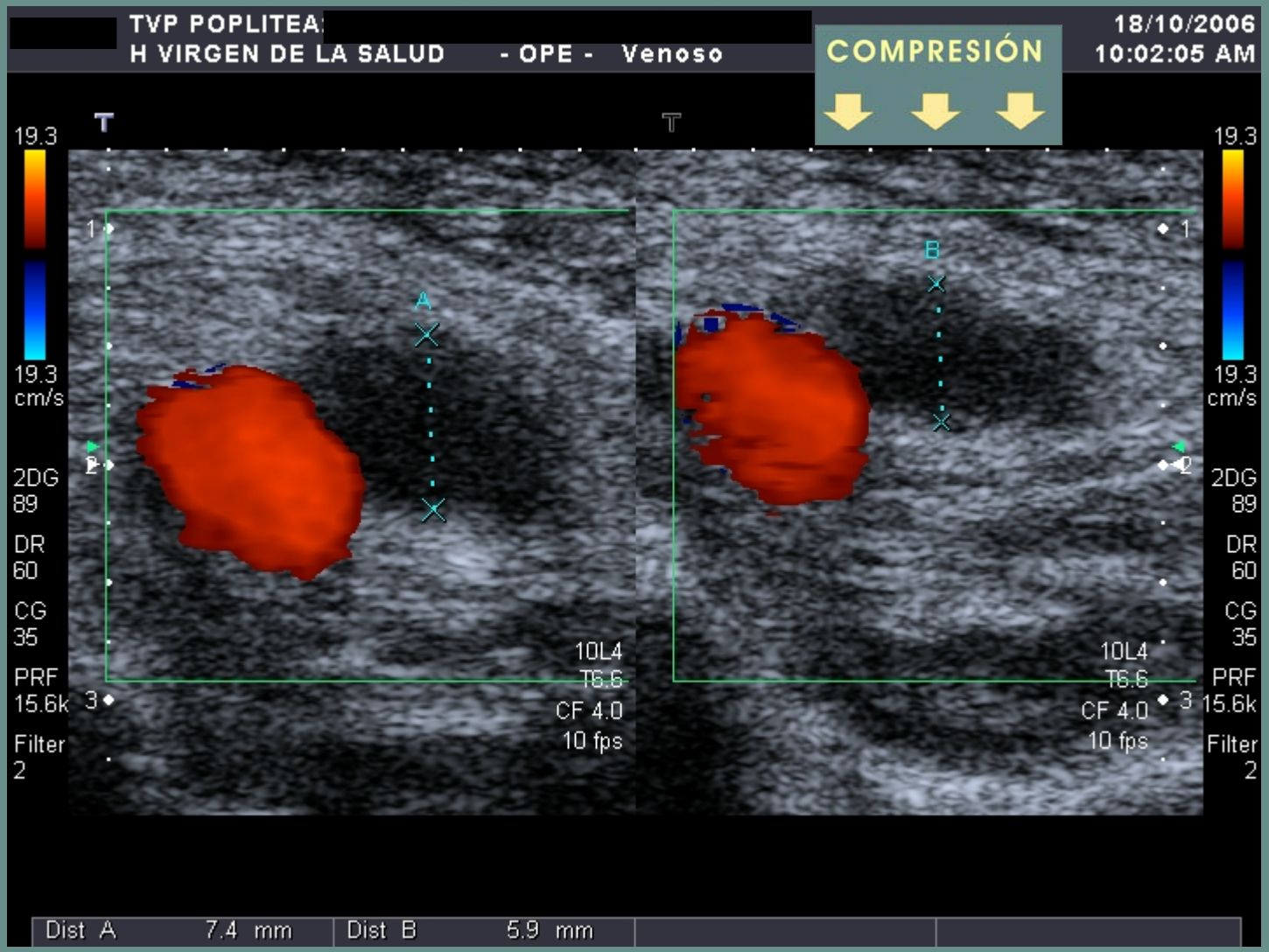

# ECO-DOPPLER. CRITERIOS DE NORMALIZACIÓN

## CRITERIOS ECO-DOPPLER DE RETROMBOSIS ( P. Prandoni )

| ECO-DOPPLER EN LA TVP AGUDA | ECO-DOPPLER DE CONTROL POST-TVP | ECO-DOPPLER ACTUAL |
|---|---|---|
| C O M P R E S I Ó N | | |
| | NORMALIZACIÓN  NO NORMALIZACIÓN | NO COMPRESIBLE AUMENTO DEL DIÁMETRO RESIDUAL EN MÁS DE 2 mm. |

# DIAGNÓSTICO DE LA TVPR BASADO EN EL ECO-DOPPLER

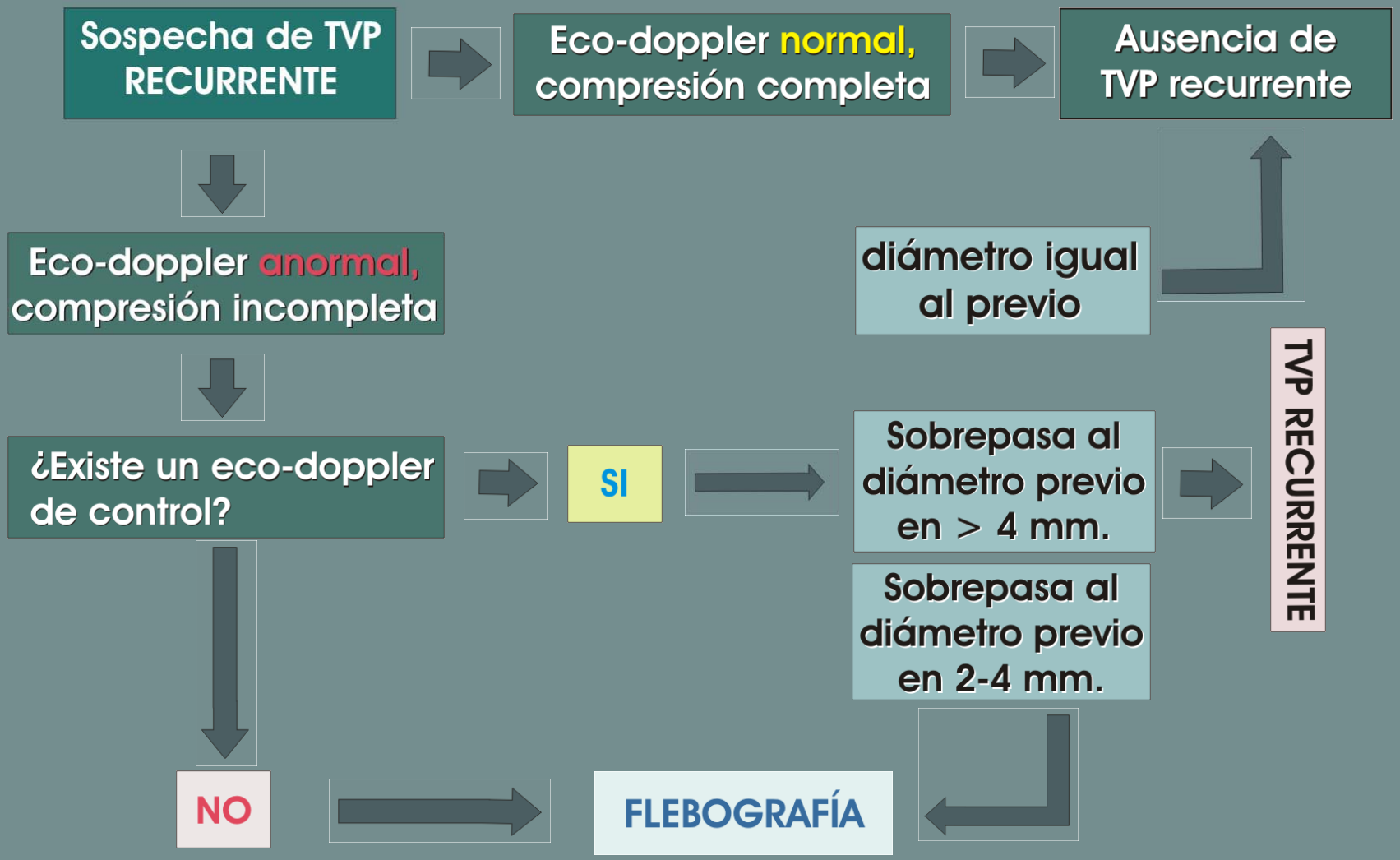


Pathophysiol Haemost Thromb 2003/2004;33:311-313

# FALTA DE PRECISIÓN EN LA MEDICIÓN

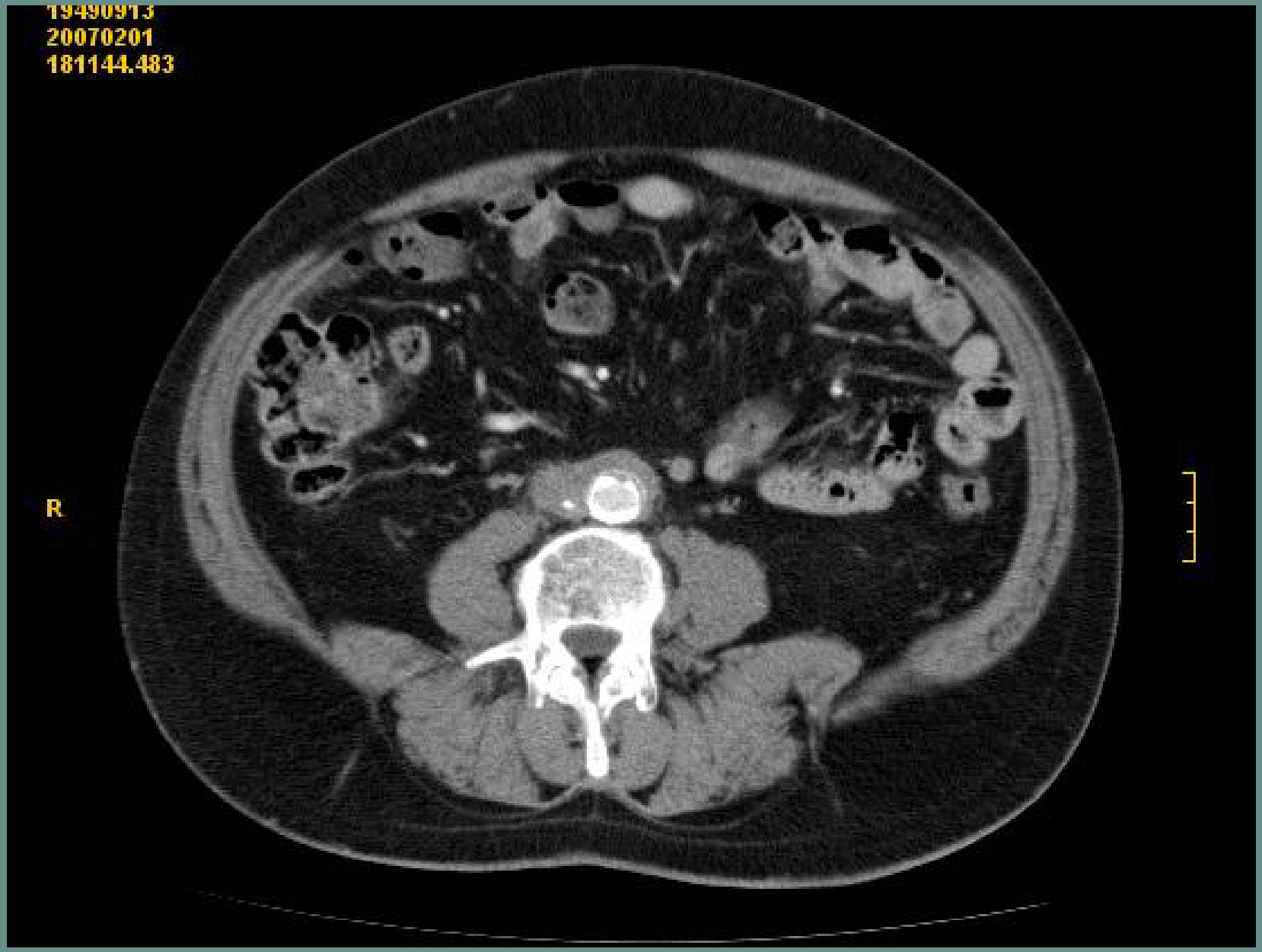
19490913
20070201
181144.483
R

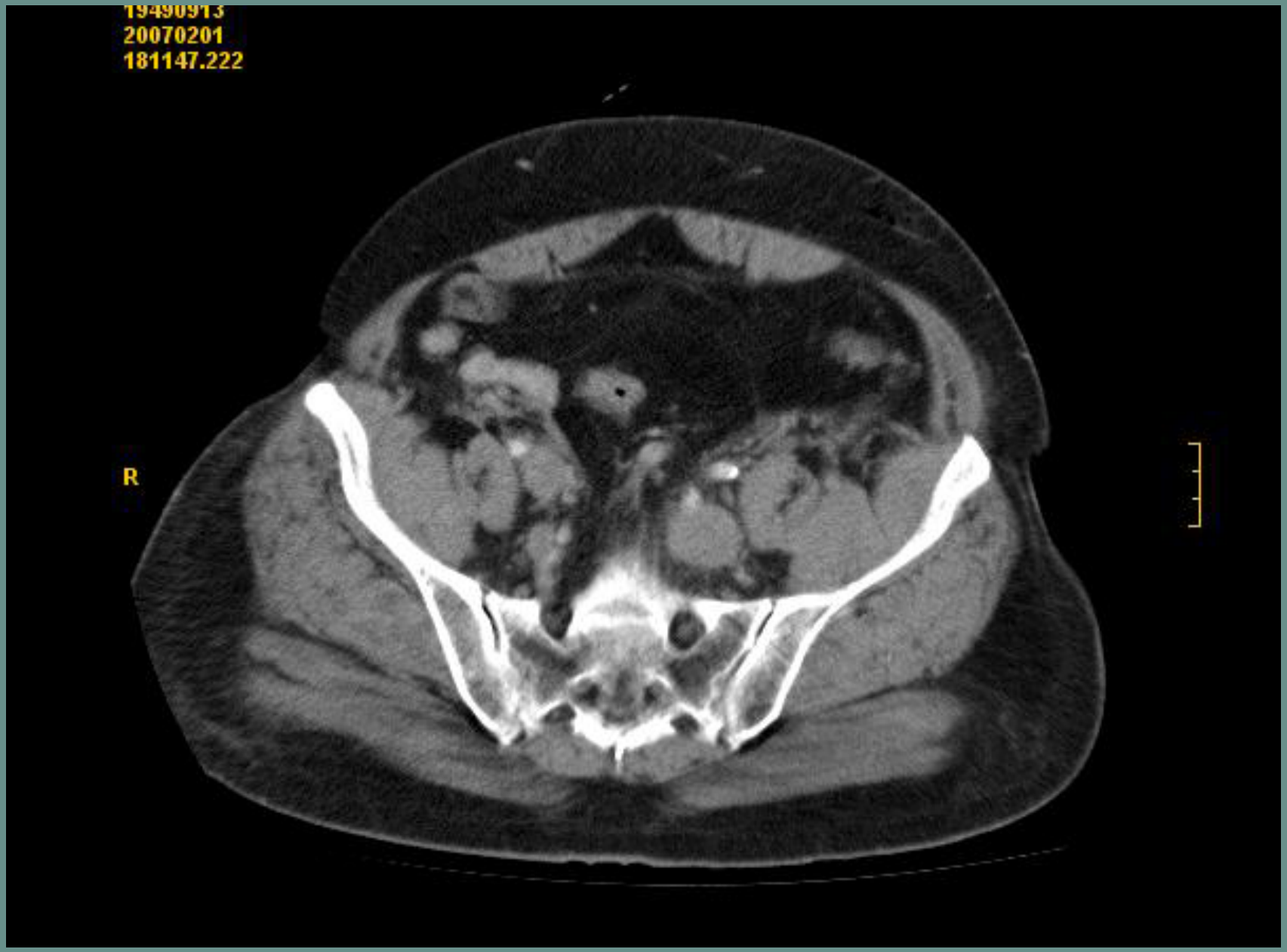
19490913
20070201
181147.222
R

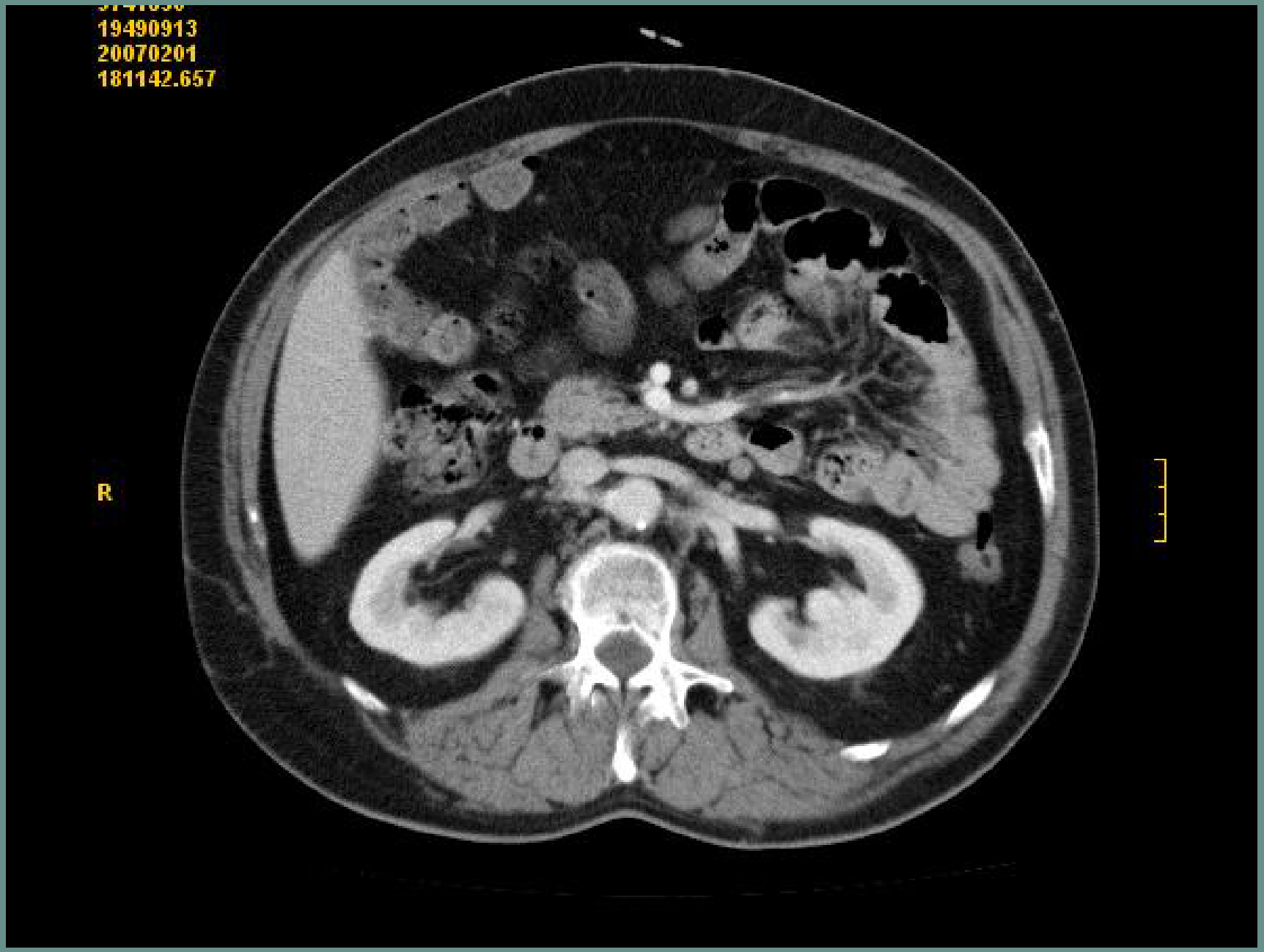
19490913
20070201
181142.657
R

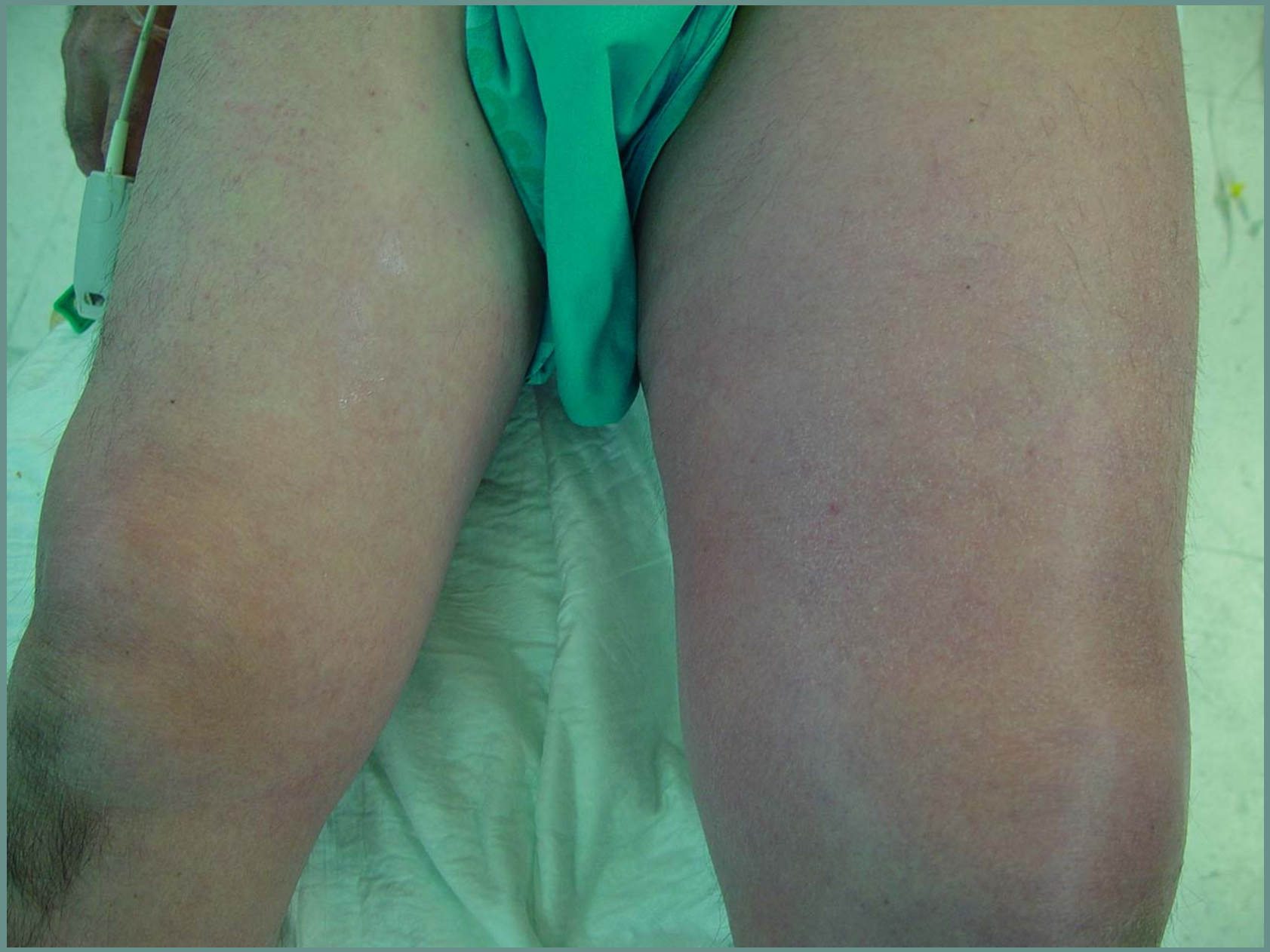

sescam
sescam
sescam

sescam

Sd. de cava inferior

Hipertensión venosa en MII
Riesgo de Sd. compartimental

Anestesia general
Trombectomía venosa
Angioplastia/stent ilio-cava

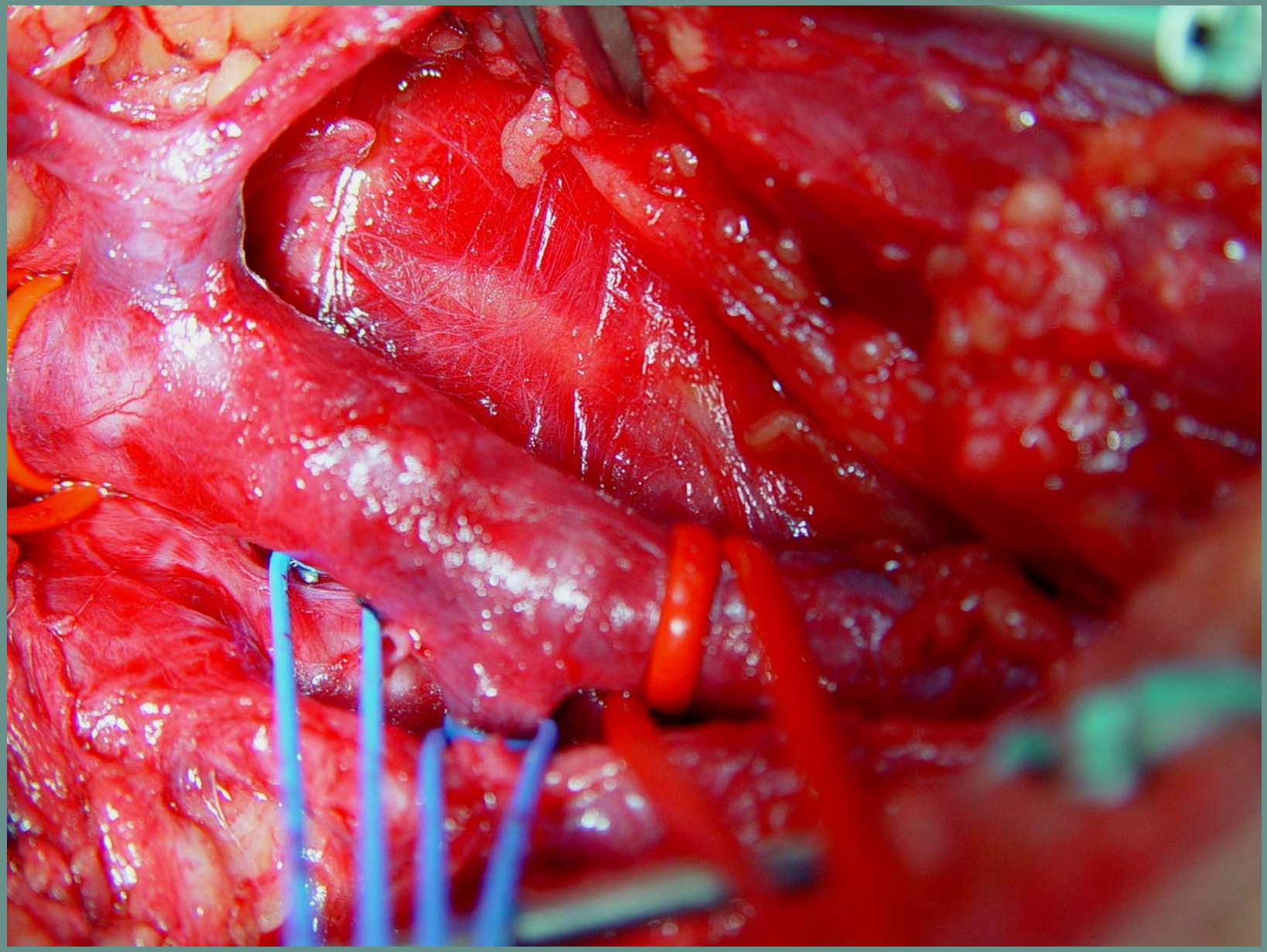

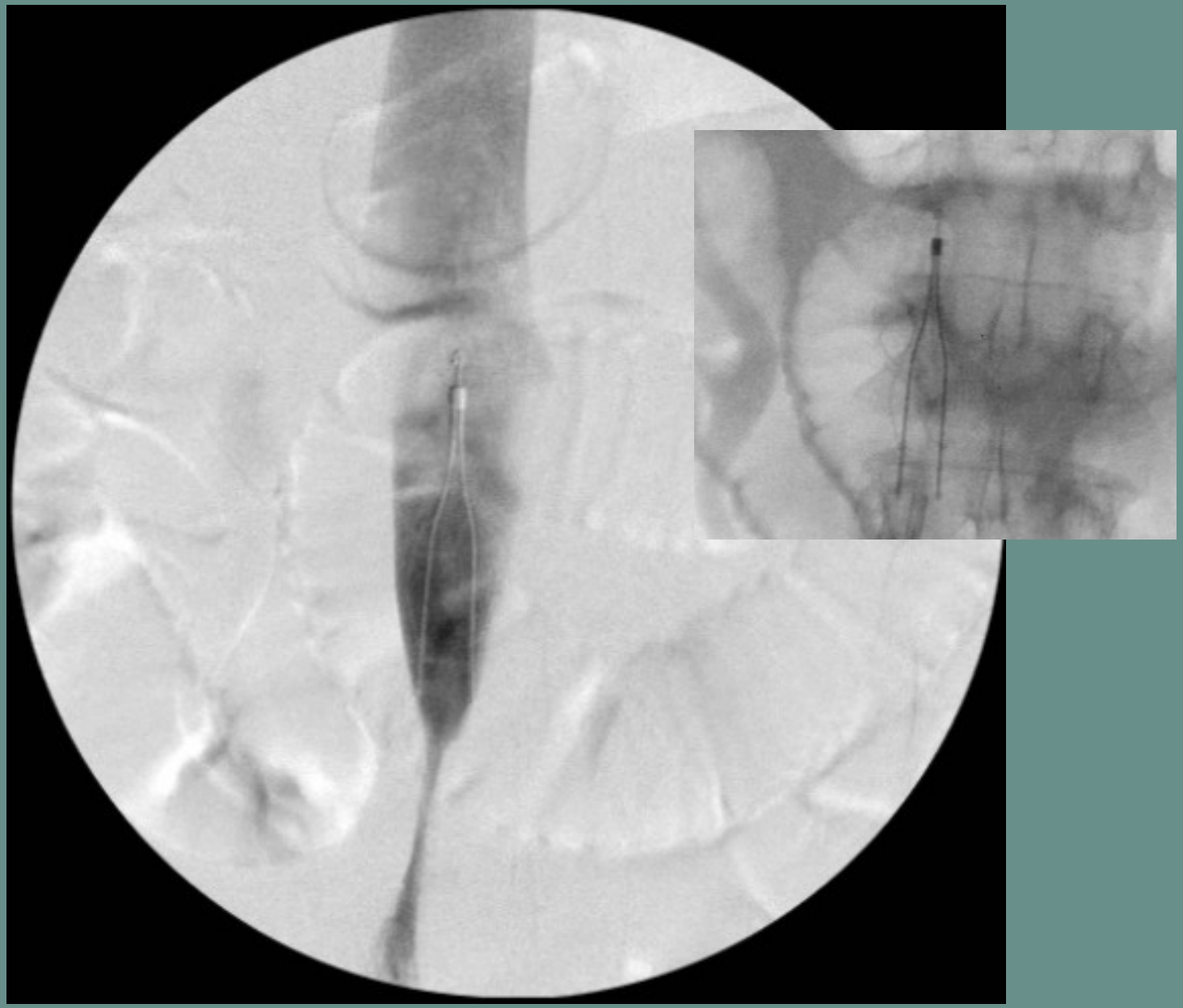

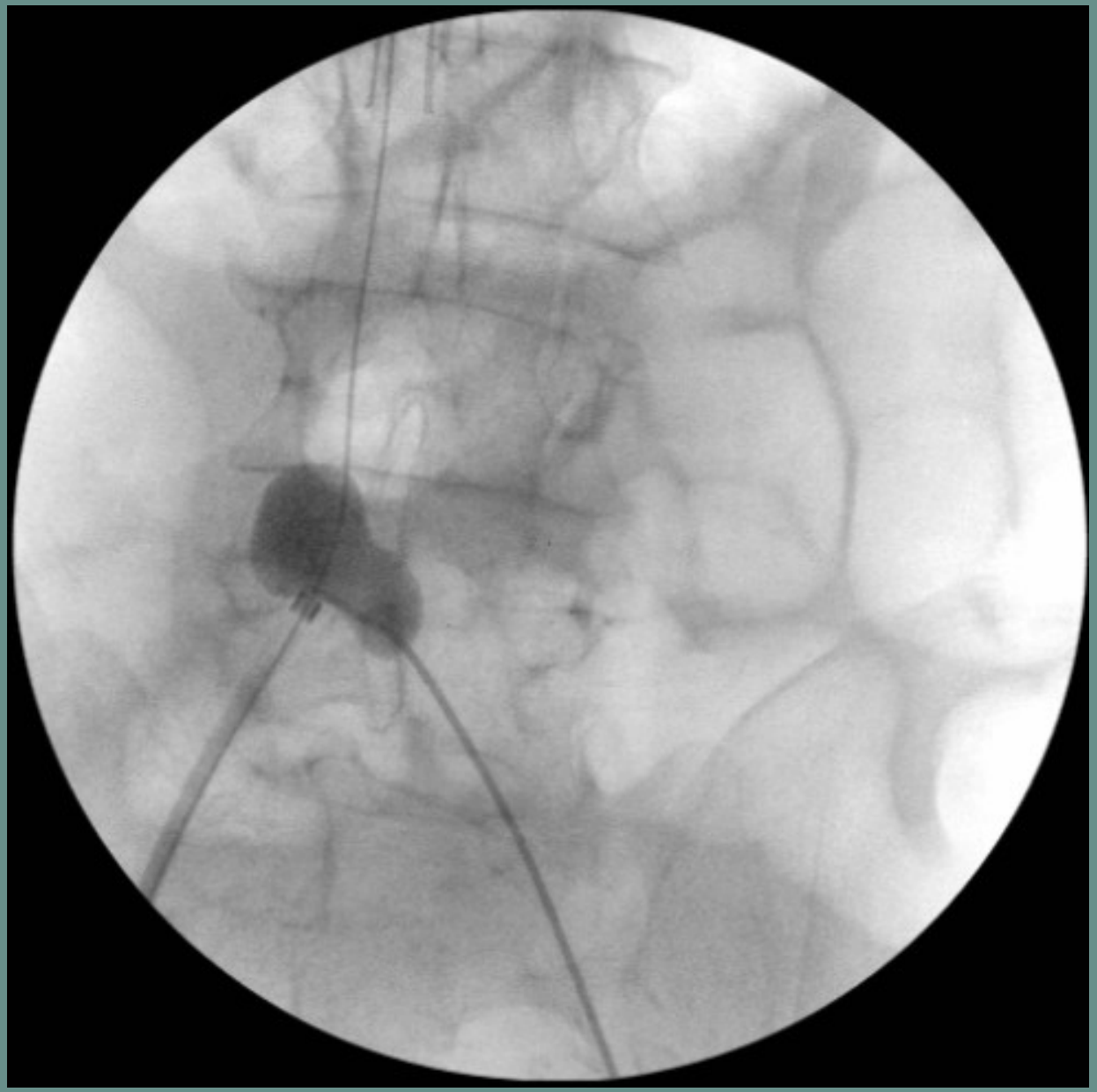

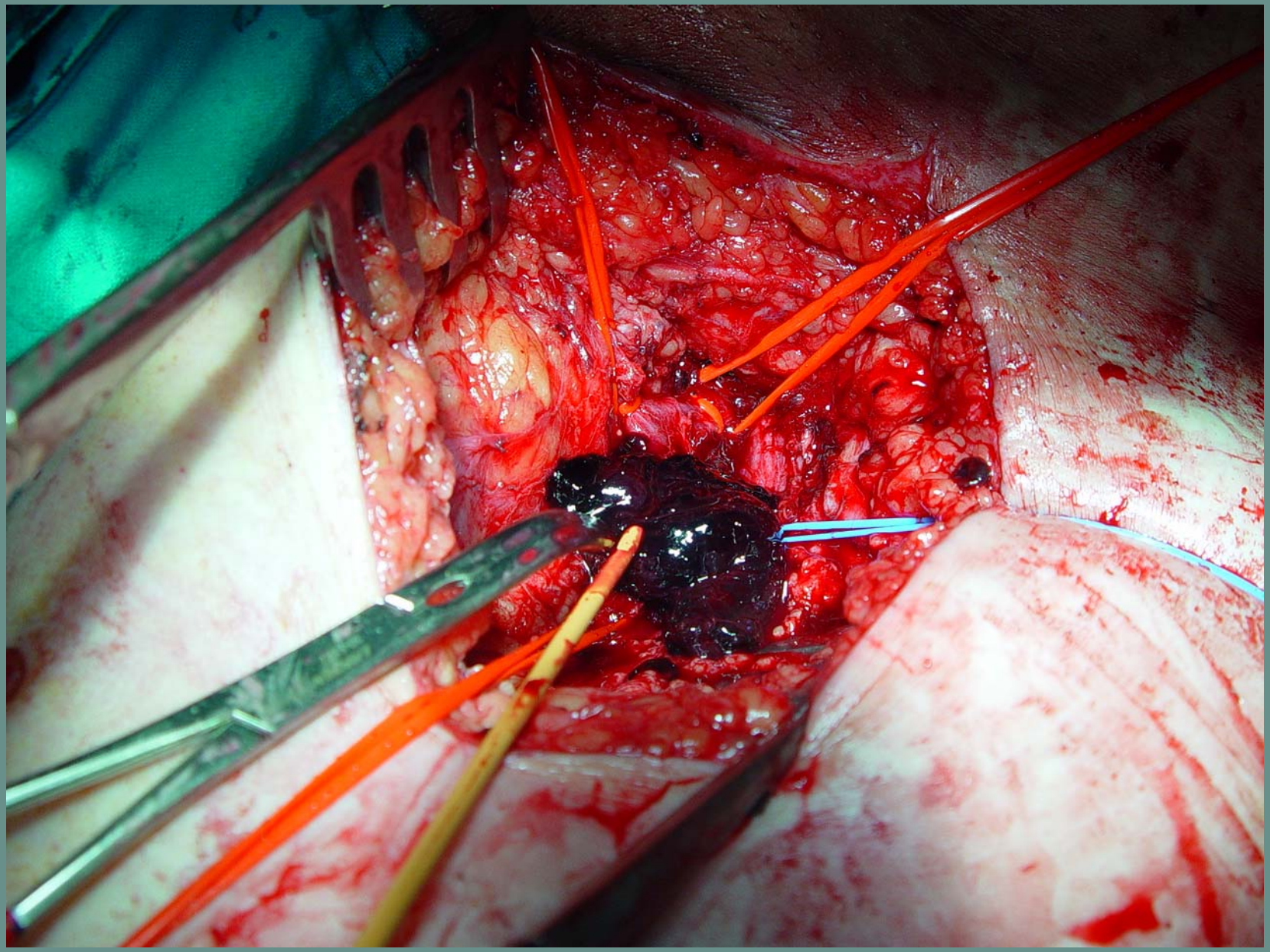

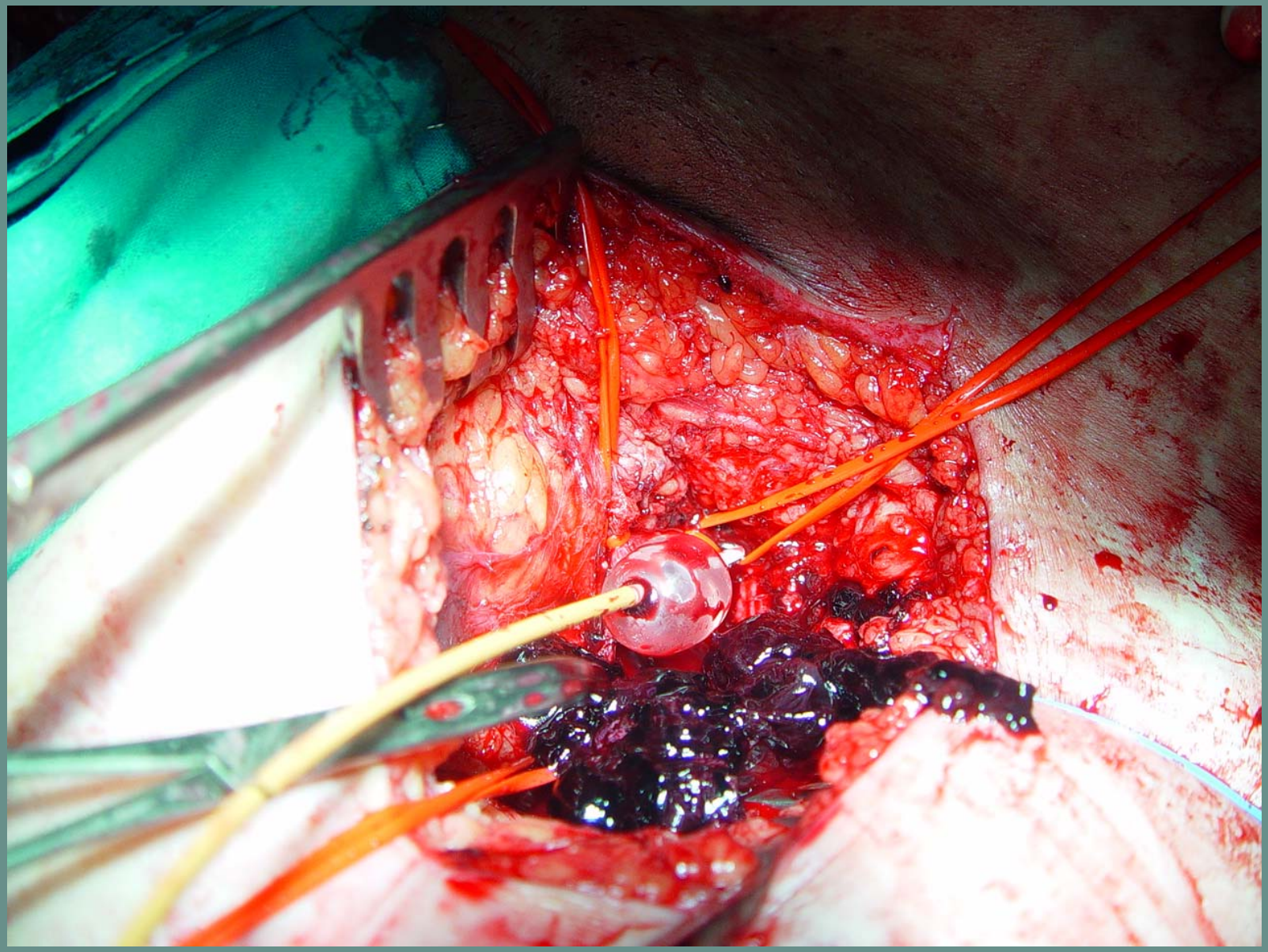

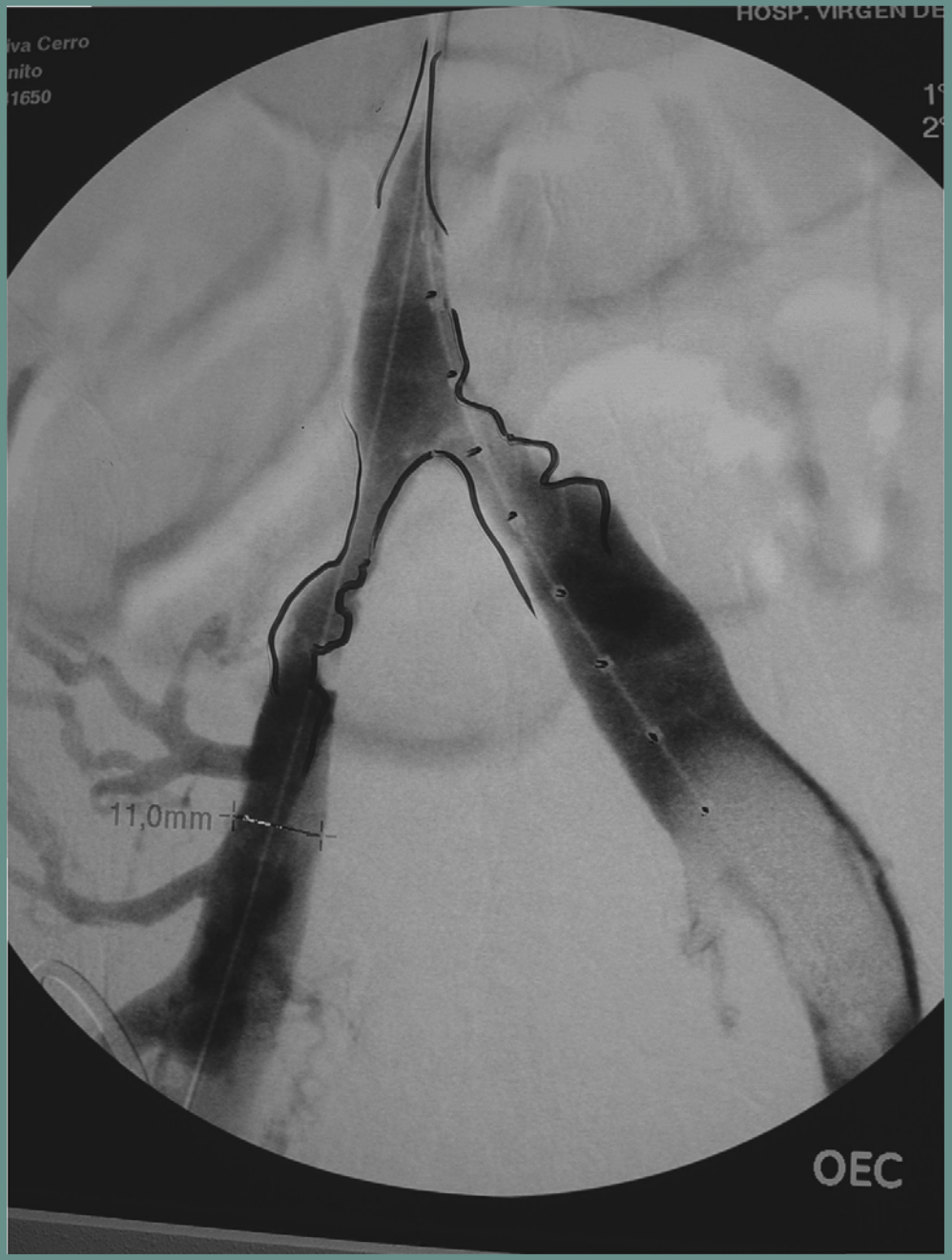
HOSP. VIRGEN DE
iva Cerro
nito
1650
11,0mm
OEC

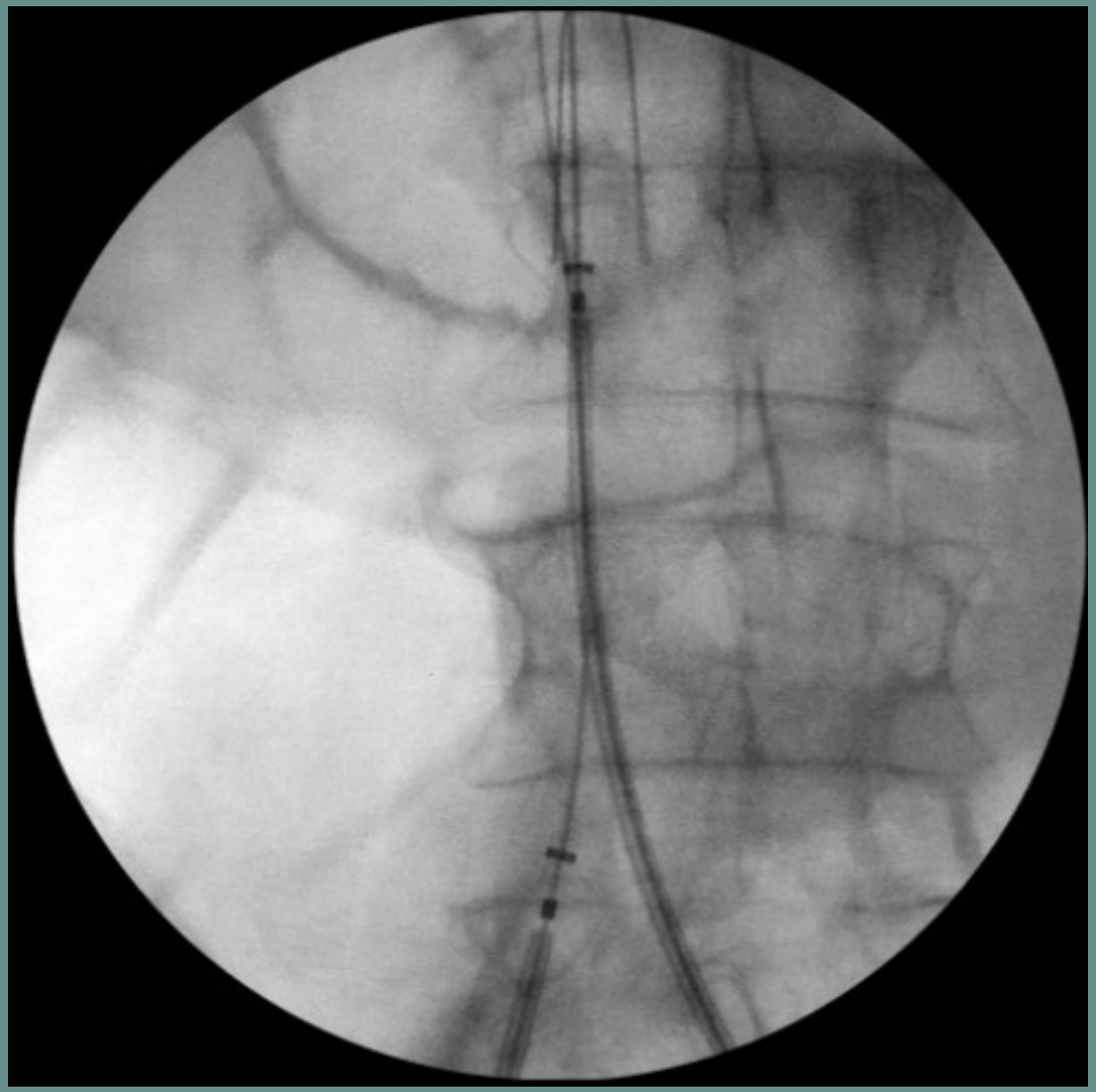

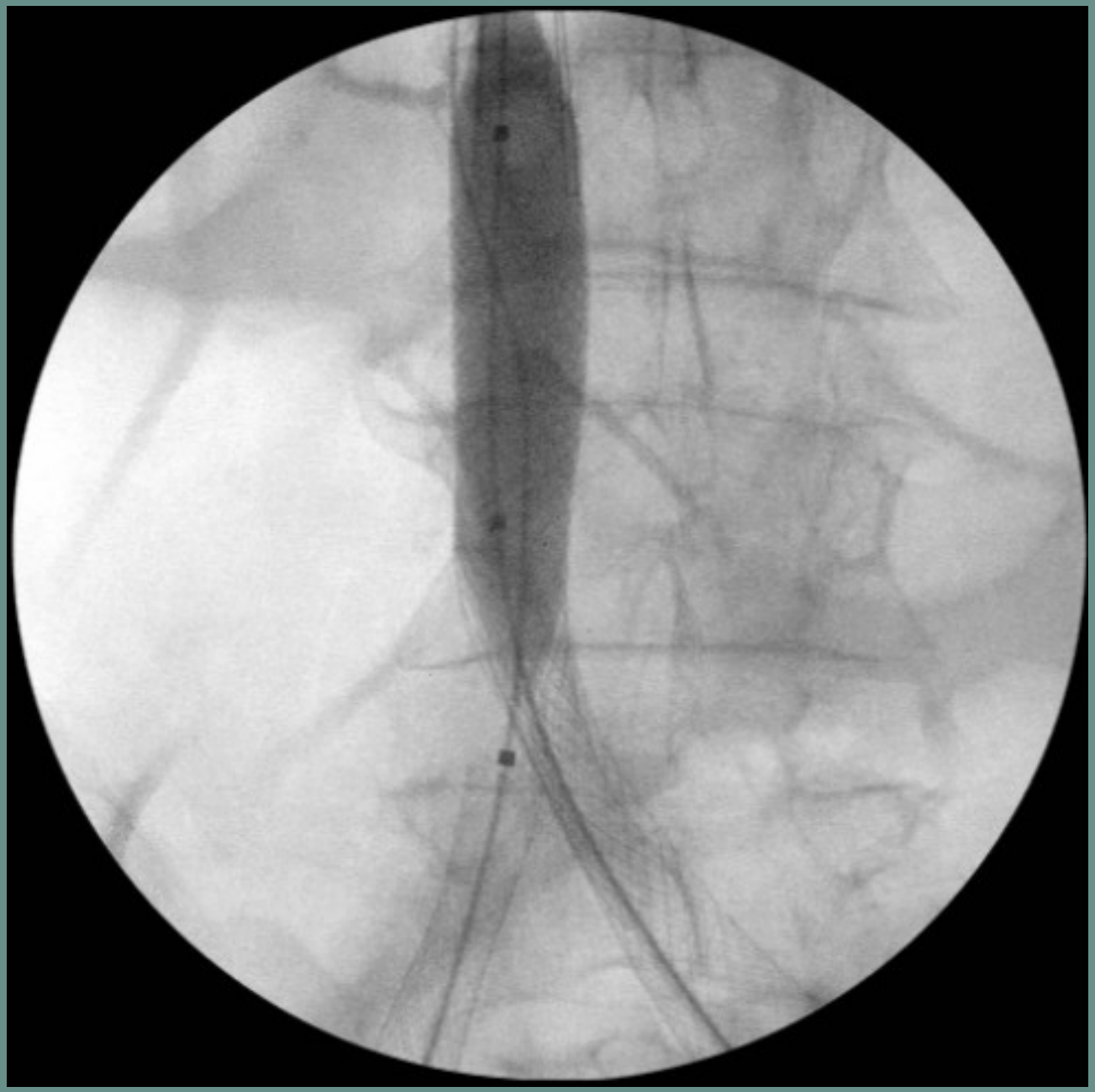

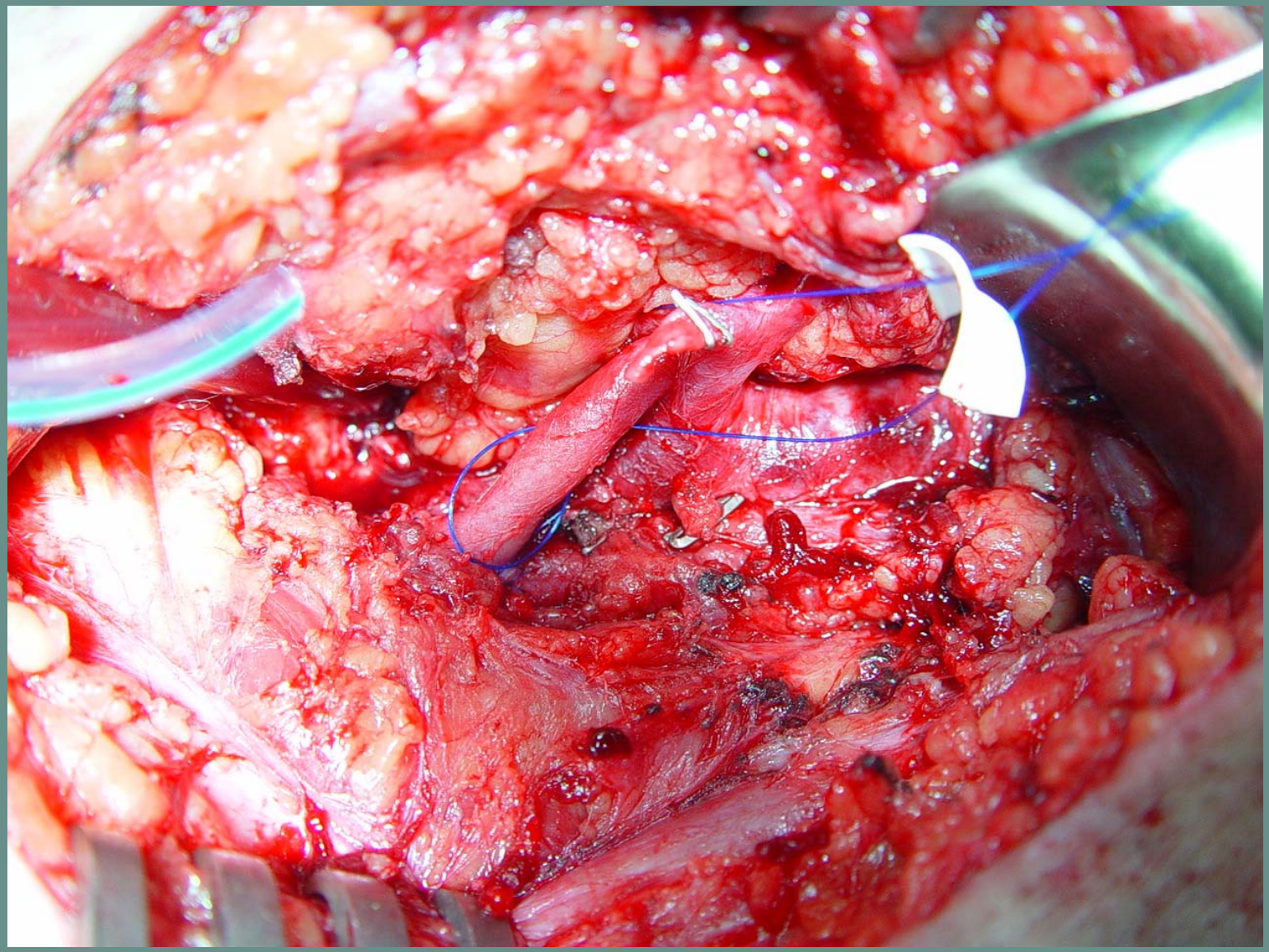

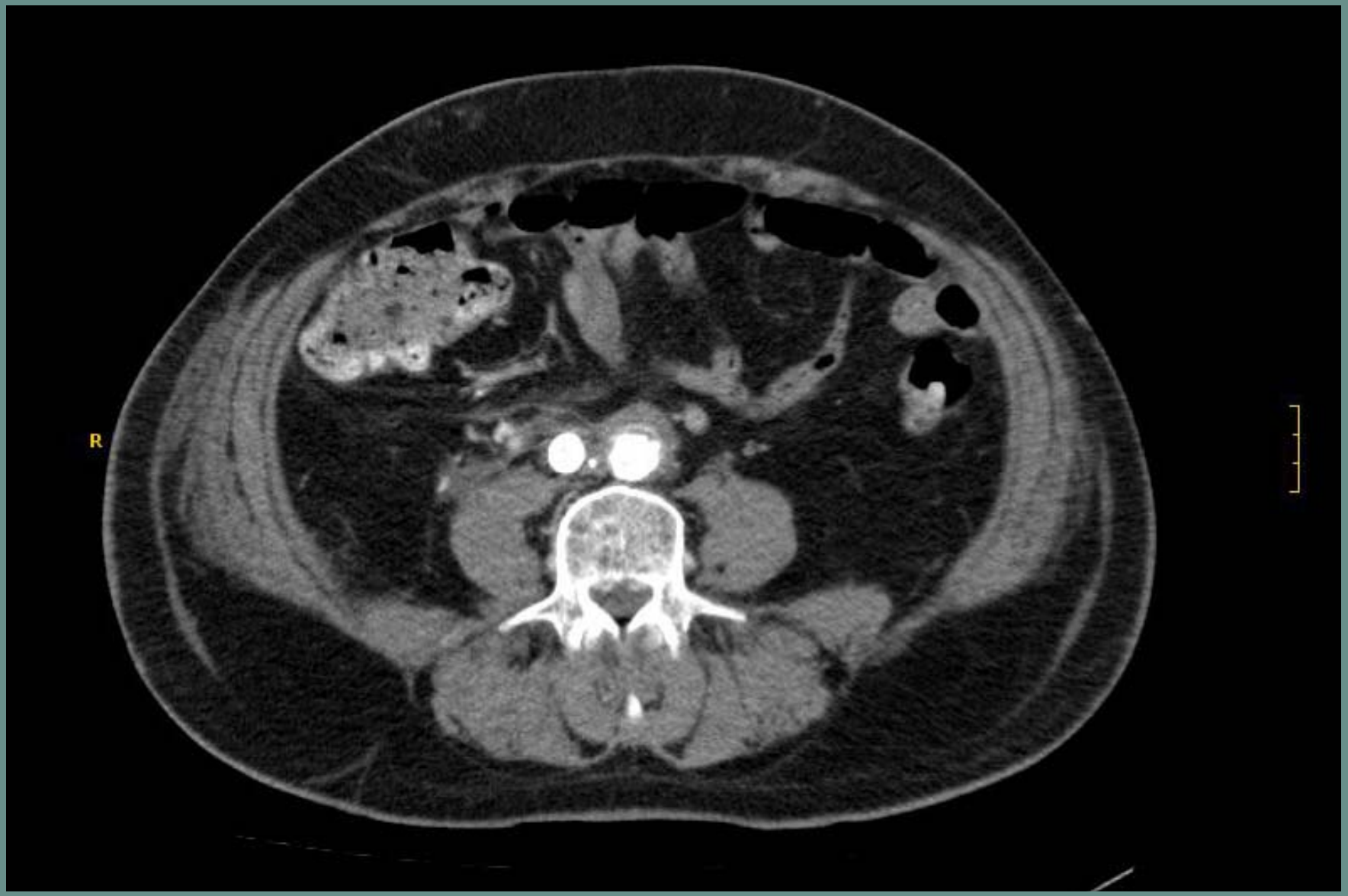
R

# CONCLUSIONES

**Sospecha de TVPR**

Criterios clínicos
Eco-doppler

**Anticoagulación**

**Sospecha de TVPR**

*Criterios clínicos*
*Eco-doppler de control tras TVP*
*Grado de normalización*
*Dímero D validado*
*Angio-CT*
*Flebografía o angio-RM*

***Anticoagulación***
***Tto endovascular***