



Miopatías Inflammatorias Idiopáticas

¿Qué hemos aprendido desde Bohan y Peter?

VI
Reunión
GEAS
Zaragoza



Albert Selva O'Callaghan

344

Historia familiar

THE NEW ENGLAND JOURNAL OF MEDICINE

Mc Ardle

Feb. 13, 1975

MEDICAL PROGRESS

POLYMYOSITIS AND DERMATOMYOSITIS (First of Two Parts)

ANTHONY BOHAN, M.D., AND JAMES B. PETER, M.D., PH.D.

Granulomas en la biopsia muscular

Evidencia de neuropatía

Vol. 292 No. 8

POLYMYOSITIS AND DERMATOMYOSITIS — BOHAN AND PETER

403

Distrofias

MEDICAL PROGRESS

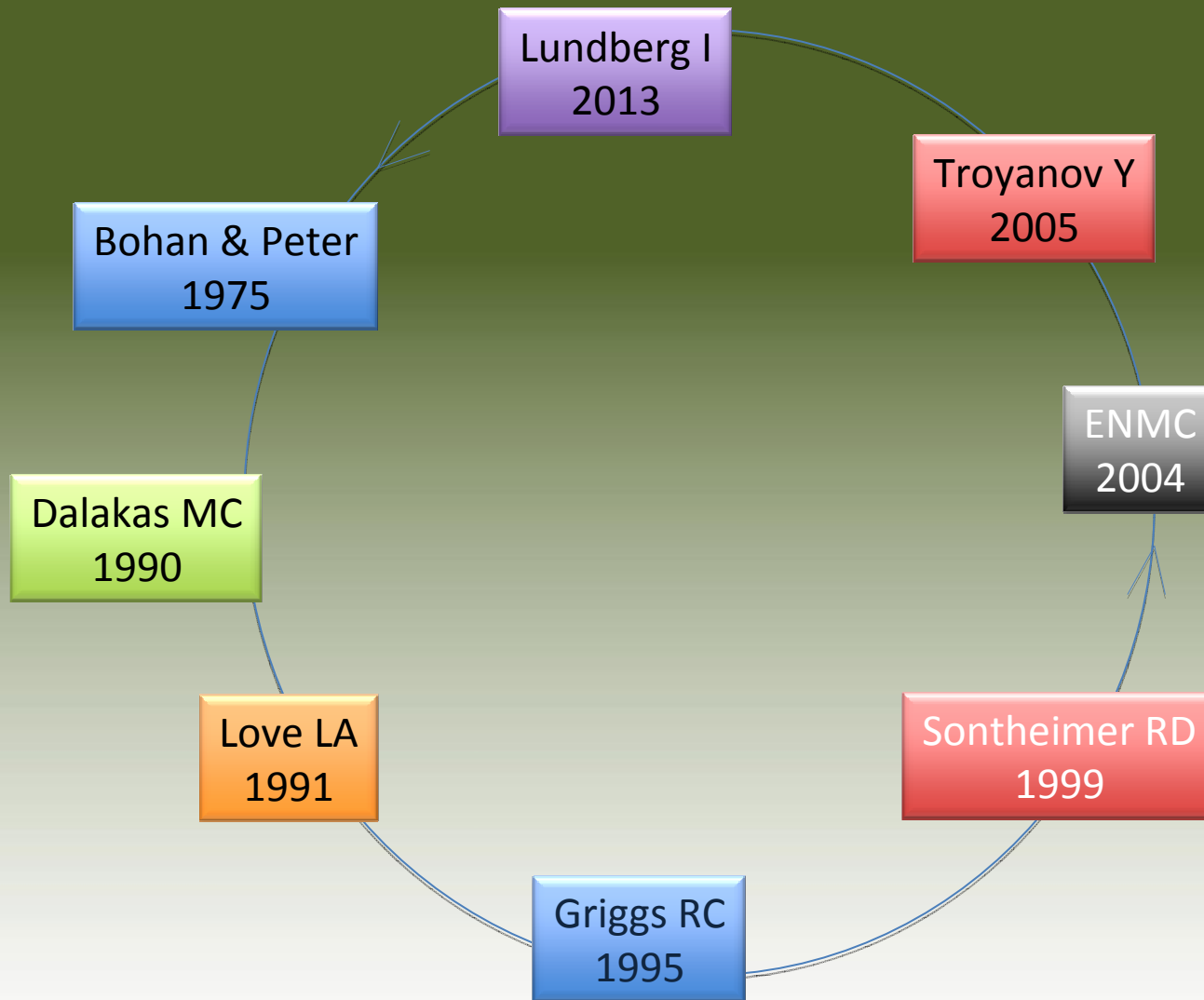
POLYMYOSITIS AND DERMATOMYOSITIS (Second of Two Parts)

ANTHONY BOHAN, M.D., AND JAMES B. PETER, M.D., PH.D.

Atrofia / hipertrofia muscular

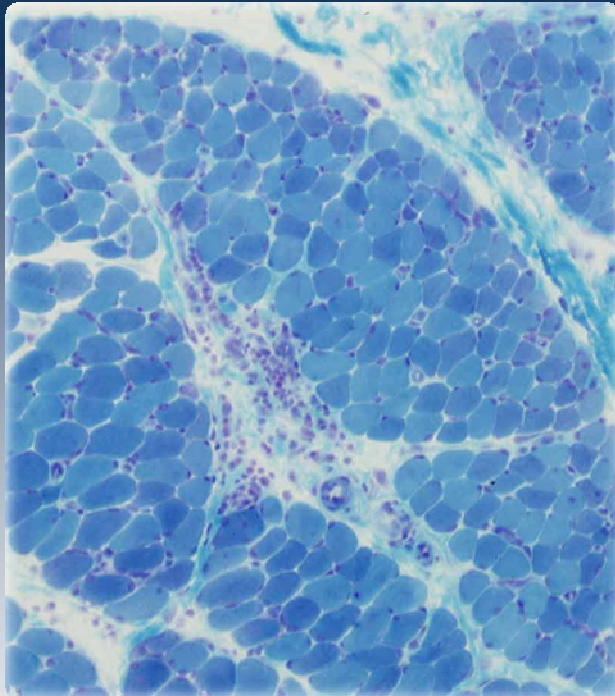
Fármacos, toxinas e infecciones

The Problem of Classification

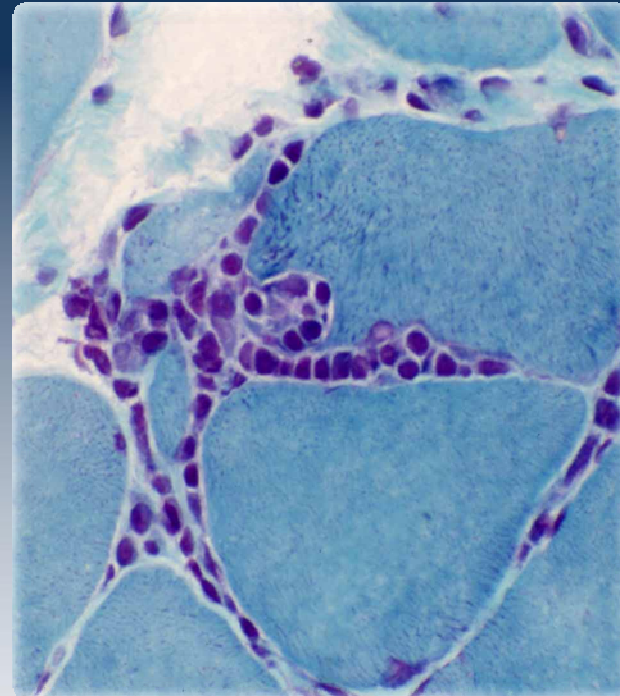


DM y PM: Enfermedades Distintas

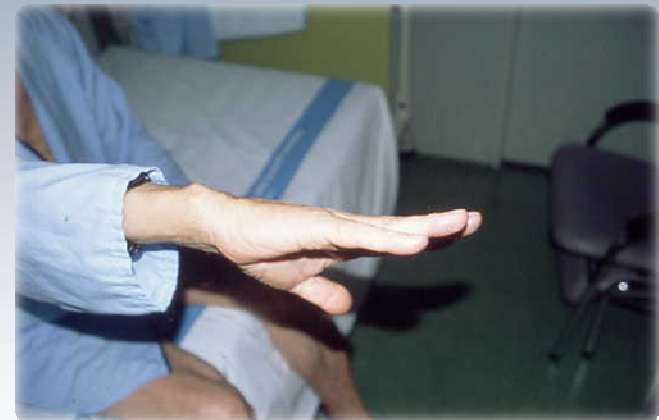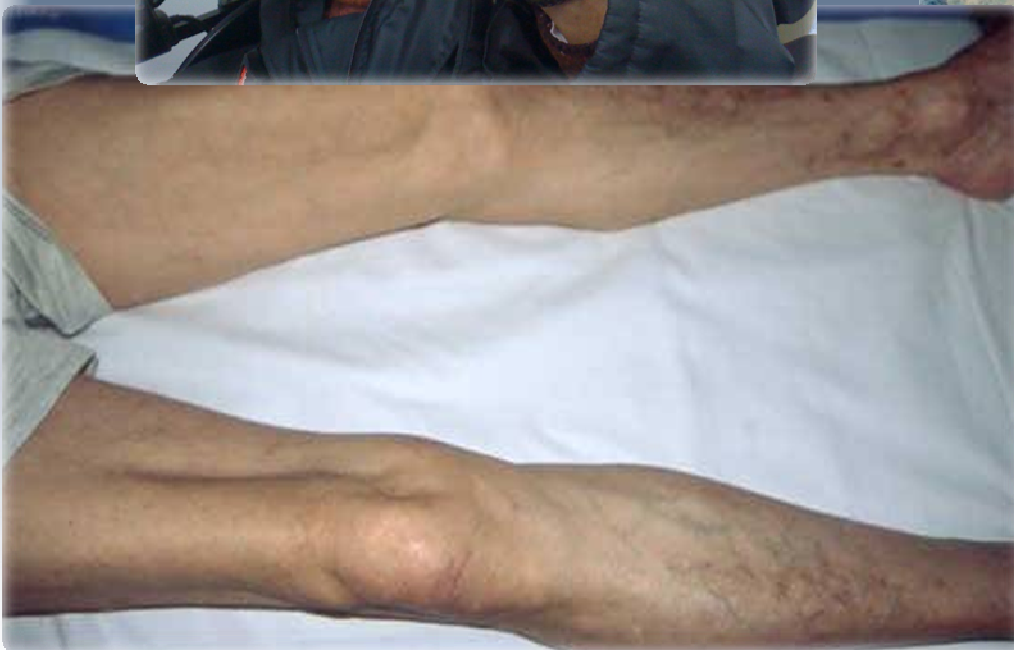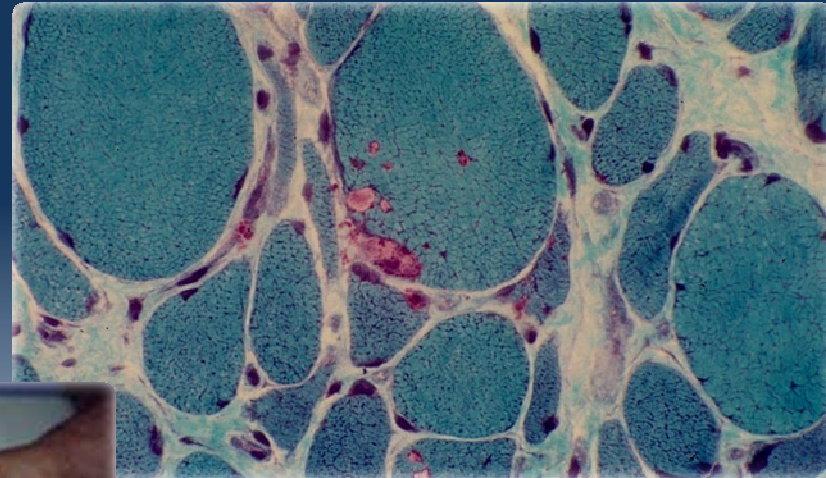
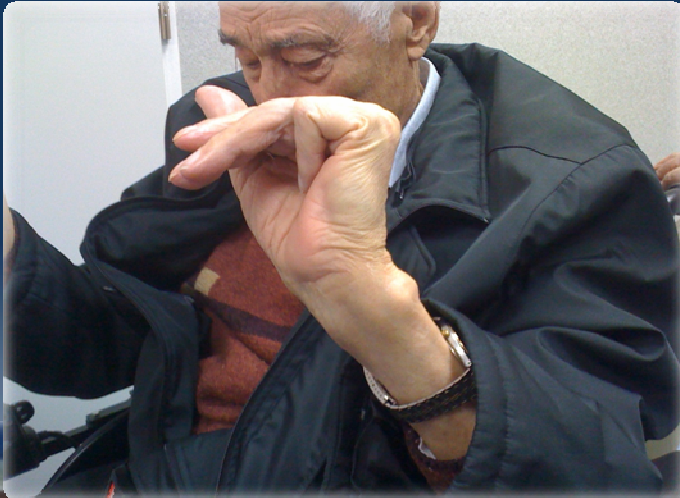DERMATOMIOSITIS



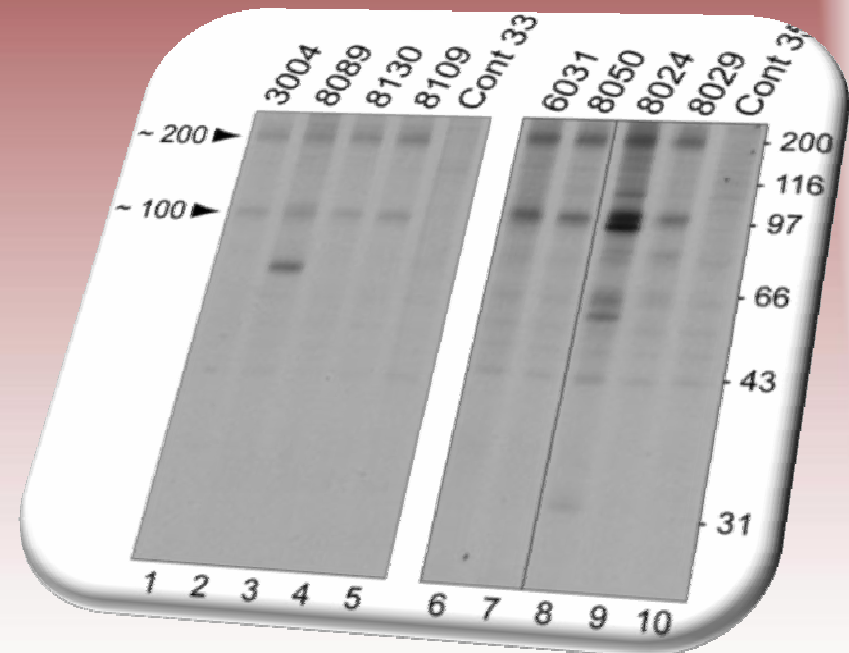
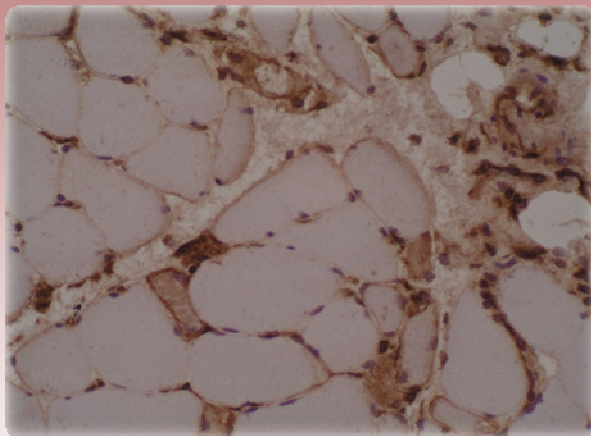
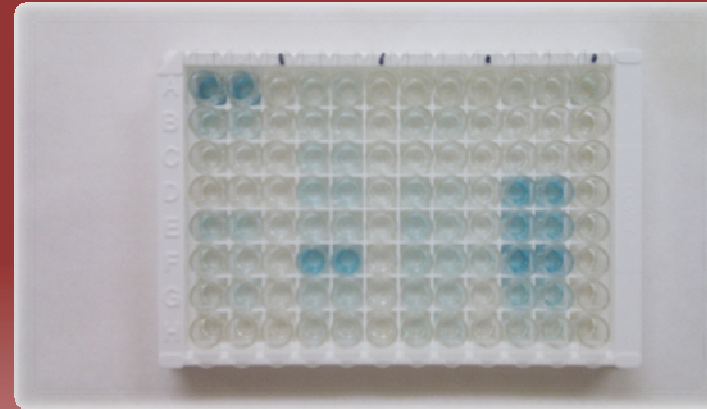
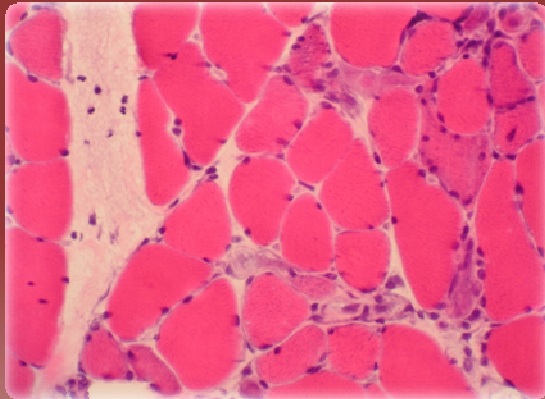
POLIMIOSITIS



Aparece una nueva MII: la MCI esporádica...



...y aún otra más, la miopatía necrosante inmunomediada



Son enfermedades sistémicas...

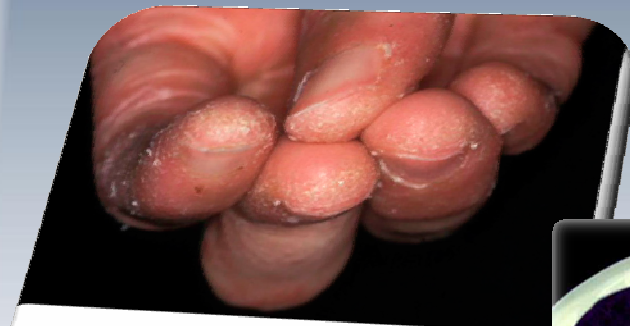
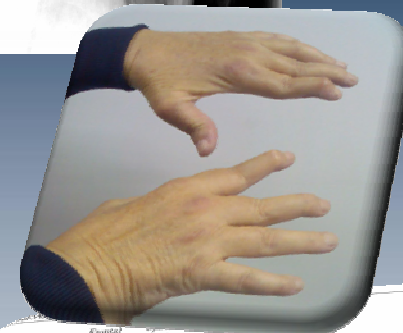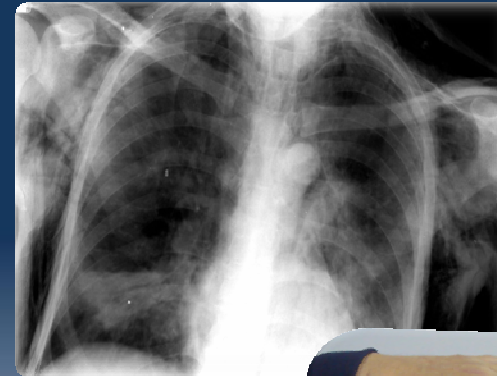
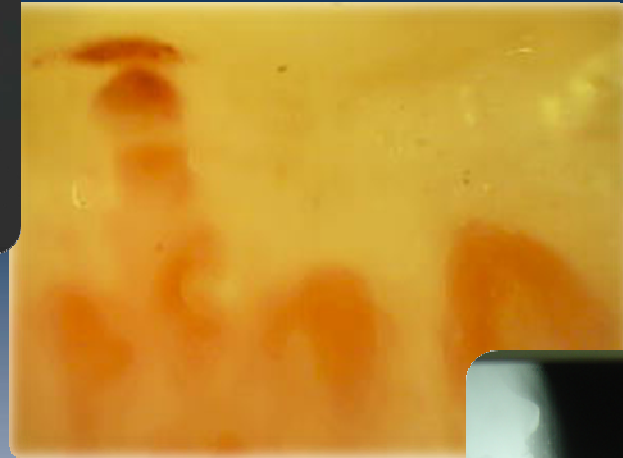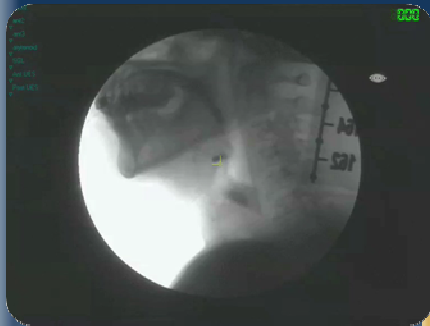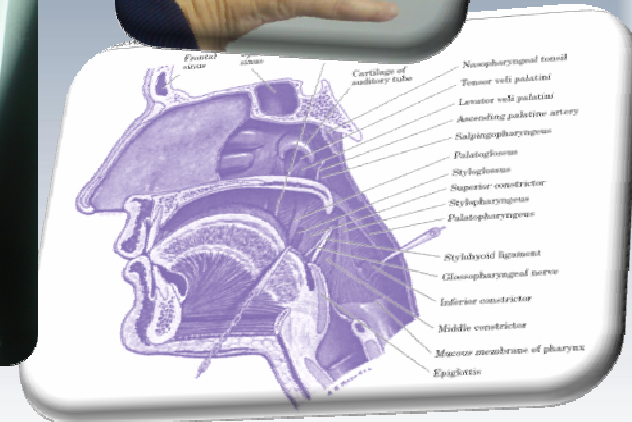
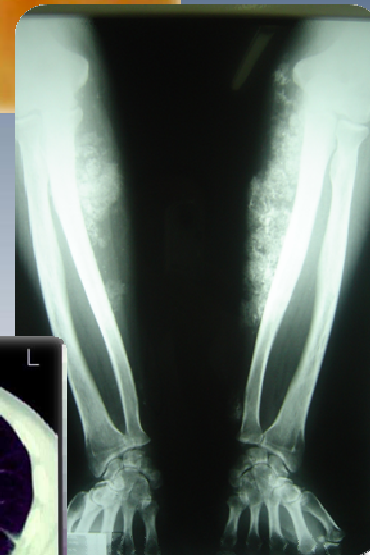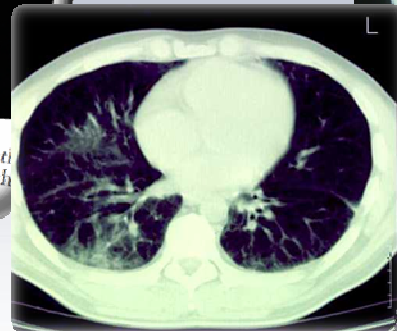


FIGURE 2. Mechanic's hand with typical skin thickening on the fingers. The patient provided written consent for the use of the photograph.



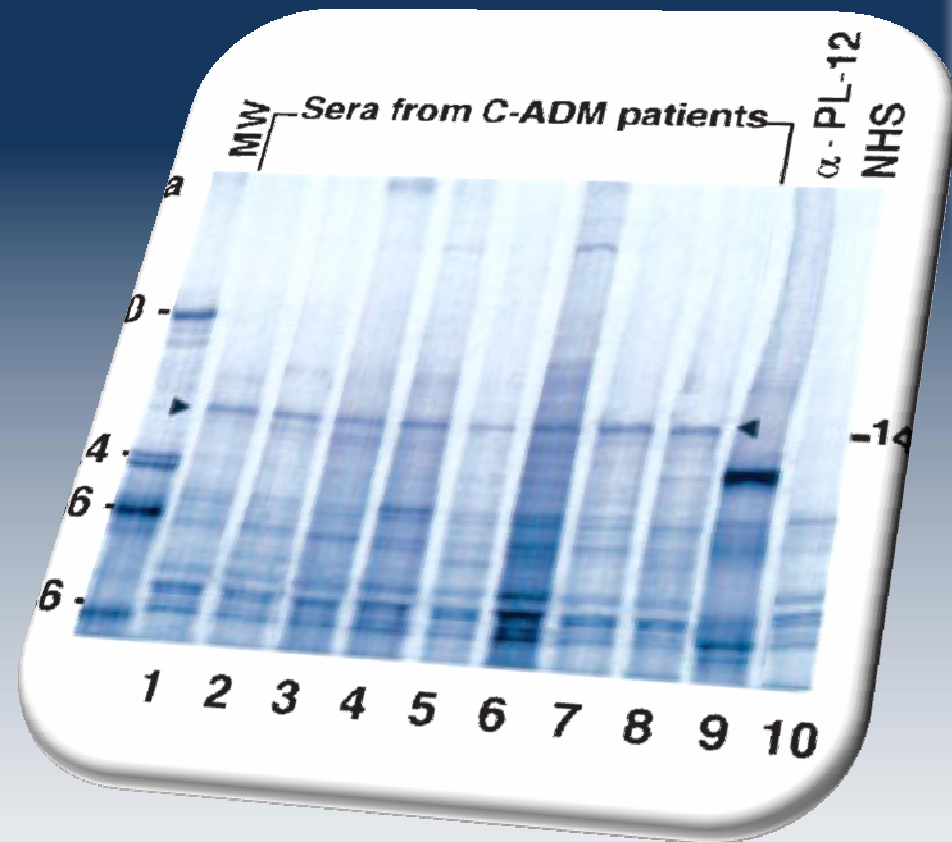
... y autoimunes

MSA (Mi-2, SRP, tRNAsintetasa)

MAA (PM/Scl, Ku, Ro/La, RNP)

Nuevos autoanticuerpos

- anti-p155 (TIF1 γ)
- anti-CADM (MDA5)
- anti-HMGR
- anti-NXP2
- anti-43 kD (TDP-43, cN1A)

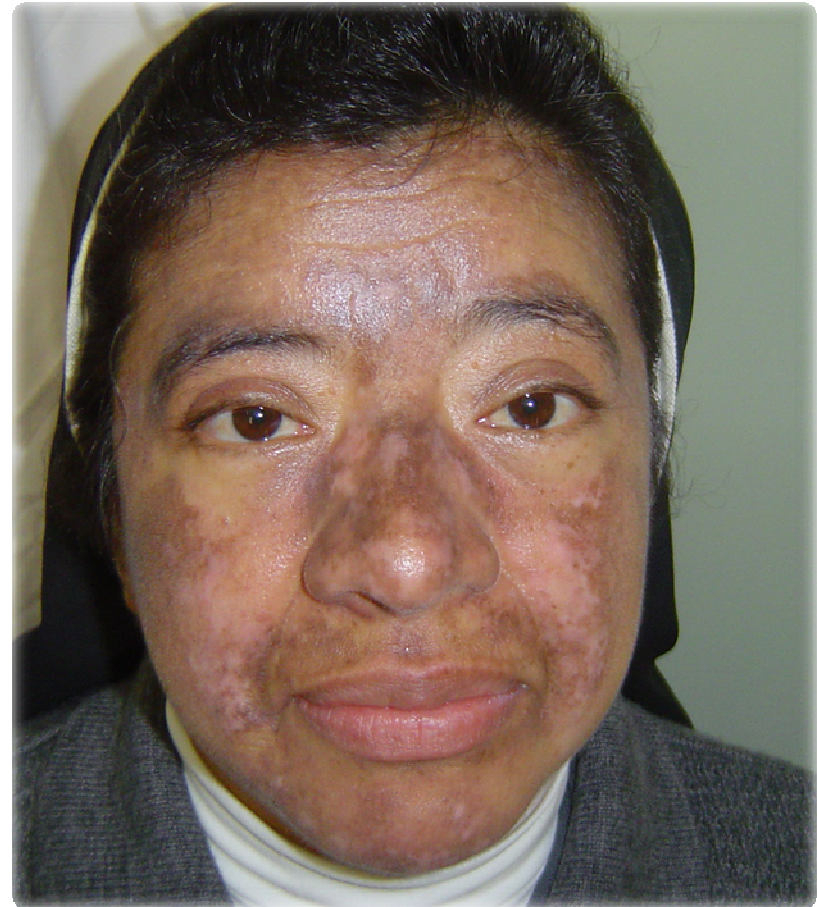

Variantes clínicas

Dermatomiositis
amiopática

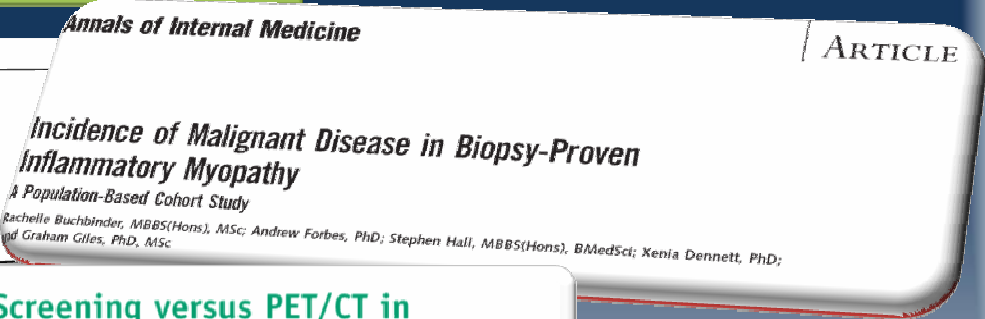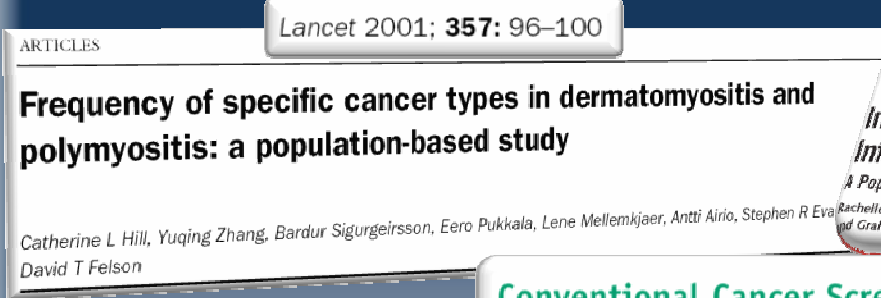
Síndrome Antisintetasa

Miositis Necrosante
Inmunomediada



...It is said that there is an increased association with neoplasia.

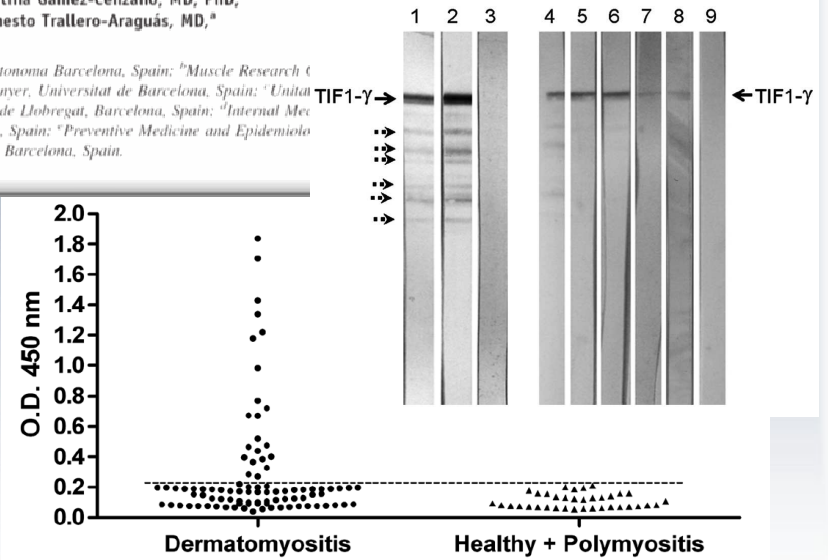
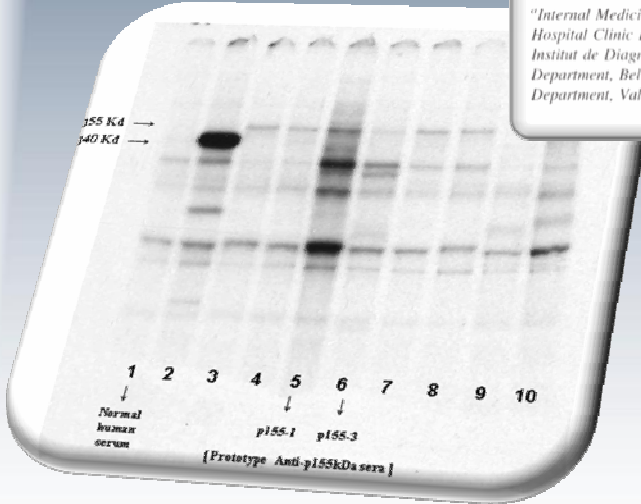
Risk of cancer in patients with dermatomyositis or polymyositis.
A population-based study. N Engl J Med. 1992; 326:363-7



Conventional Cancer Screening versus PET/CT in Dermatomyositis/Polymyositis

Albert Selva-O'Callaghan, MD, PhD,^{a*} Josep M. Grau, MD, PhD,^{b*} Cristina Gámez-Cenzano, MD, PhD,^c Antonio Vidaller-Palacín, MD, PhD,^d Xavier Martínez-Gómez, MD,^e Ernesto Trallero-Araguás, MD,^e Eduard Andia-Navarro, MD,^f Miquel Vilardell-Tarrés, MD, PhD^g

^aInternal Medicine Department Vall d'Hebron General Hospital, Universitat Autònoma Barcelona, Spain; ^bMuscle Research Hospital Clínic Provincial, Institut d'Investigacions Biomèdiques August Pi i Suñer, Universitat de Barcelona, Spain; ^cUnitat d'Immunologia, Institut de Diagnòstic per la Imatge, Bellvitge Hospital, IDIBELL, L'Hospitalet de Llobregat, Barcelona, Spain; ^dInternal Medicine Department, Bellvitge Hospital, IDIBELL, L'Hospitalet de Llobregat, Barcelona, Spain; ^ePreventive Medicine and Epidemiology Department, Vall d'Hebron General Hospital, Universitat Autònoma Barcelona, Barcelona, Spain.



Nuevas opciones terapéuticas

Inmunodepresores (MTX, AZA)

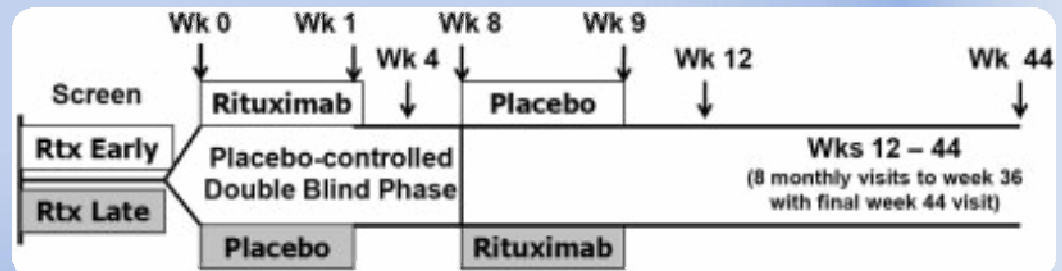
Inmunomoduladores (antagonistas de la calcineurina: tacrolimus, ciclosporina)

Inmunoglobulinas e.v.

Terapias biológicas (ensayos de signación aleatoria y controlados con placebo)

. Etanercept

- Estudio RIM (rituximab)



Fact, Fancy, and Fiction (1975)

...an association between dermatomyositis and neoplasia...

...The relative frequencies of polymyositis and dermatomyositis have been established...

...The muscle biopsy in patients with dermatomyositis and neoplasia may be unusual in lacking inflammatory cells and phagocytosis, despite profound necrosis of muscular fibers...

...The natural history of polymyositis and dermatomyositis is known...

...An extensive work-up for neoplasia must be performed in any patient diagnosed as having polymyositis or dermatomyositis...

Fact, Fancy, and Fiction (2013)

...an association between dermatomyositis and neoplasia...

...The relative frequencies of polymyositis and dermatomyositis have been established...

...The muscle biopsy in patients with dermatomyositis and neoplasia may be unusual in lacking inflammatory cells and phagocytosis, despite profound necrosis of muscular fibers...

...The natural history of polymyositis and dermatomyositis is known...

...An extensive work-up for neoplasia must be performed in any patient diagnosed as having polymyositis or dermatomyositis...

Miopatías Inflammatorias Idiopáticas


¿Y qué nos queda por conocer?

“...si no sabes a donde vas, tampoco sabrás que has llegado...”



Alicia en el País de las Maravillas
Lewis Carroll, 1865

Innumerables interrogantes...

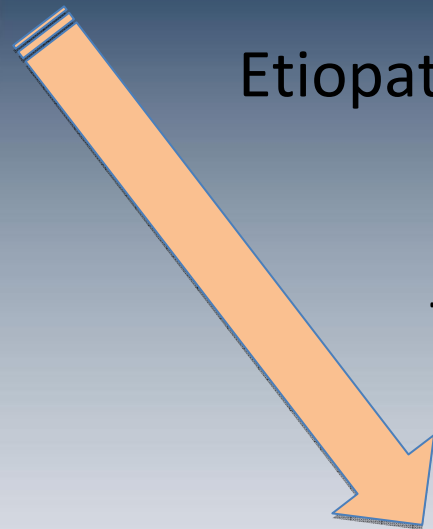


Etiología

GWAS

Etiopatogenia

Tratamiento



¿Cuál/es son los principales agentes etiológicos?

¿Qué mecanismos actúan en la producción de la enfermedad?

¿Cuál/es son los tratamientos de elección y en que situaciones?

¿Que papel desempeñan los nuevos autoanticuerpos descritos en estas enfermedades?

¿Un mejor conocimiento de la bases fisiopatológicas e inmunológicas de la relación entre cáncer y dermatomiositis, ayudará a curar el cáncer?