MANEJO ENDOVASCULAR EN EL ICTUS ISQUEMICO: ¿PRESENTE, FUTURO?

Dra. Sonia Mosteiro Añón

Secc. NeuroRadiología Intervencionista
Serv. Radiología. C.H.U. Juan Canalejo A Coruña

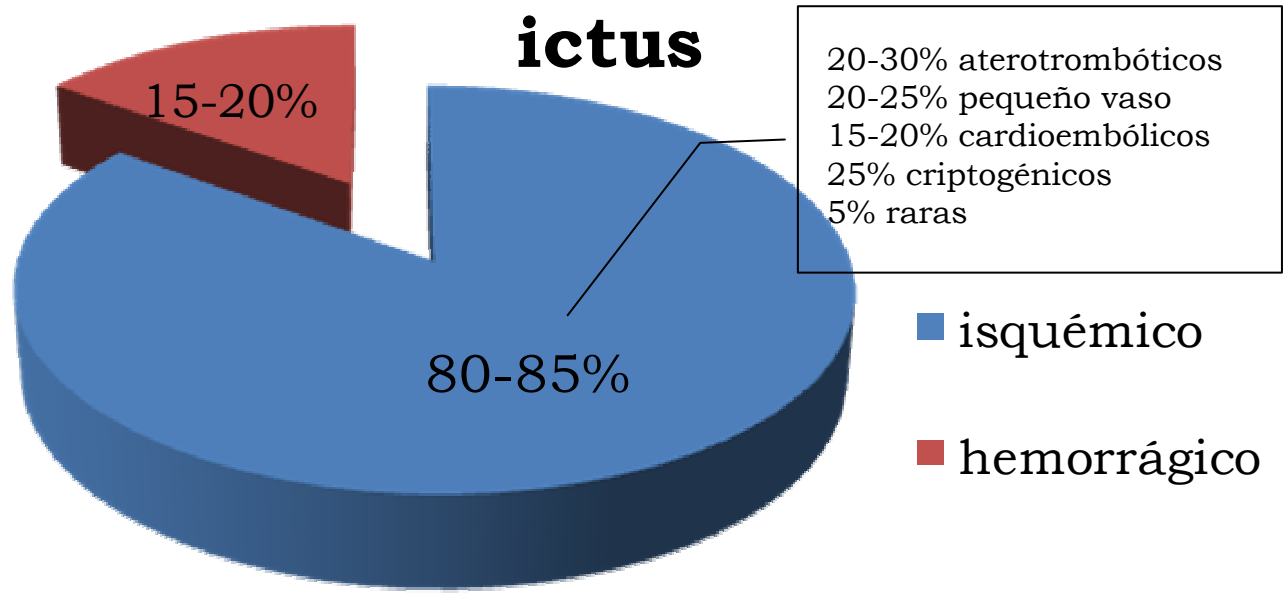

REPERFUSIÓN TEMPRANA, ESPONTÁNEA O INDUCIDA, MEJORA LOS RESULTADOS CLÍNICOS, SALVANDO PRESUMIBLEMENTE EL TEJIDO ISQUÉMICO EN RIESGO DE INFARTO

FIBRINOLISIS INTRAVENOSA

The New England
Journal of Medicine

©Copyright, 1995, by the Massachusetts Medical Society

Volume 333 DECEMBER 14, 1995 Number 24

TISSUE PLASMINOGEN ACTIVATOR FOR ACUTE ISCHEMIC STROKE

THE NATIONAL INSTITUTE OF NEUROLOGICAL DISORDERS AND STROKE rt-PA STROKE STUDY GROUP*

Conclusions. Despite an increased incidence of symptomatic intracerebral hemorrhage, treatment with intravenous t-PA within three hours of the onset of ischemic stroke improved clinical outcome at three months. (N Engl J Med 1995;333:1581-7.)

FIBRINOLISIS INTRAVENOSA

VENTANA TERAPÉUTICA

ECASS-I ---- [illegible] ras
(1,1mg [illegible] A i.v.)
ECASS-II - [illegible] **3 HORAS** [illegible] s
(0,9mg/ [illegible] rtPA [illegible]
ATLANTIS ---- [illegible] oras

2%

pacientes ictus isquémico

Economic Benefit of Increasing Utilization of Intravenous Tissue Plasminogen Activator for Acute Ischemic Stroke in the United States
Bart M. Demaerschalk and Todd R. Yip
Stroke 2005;36;2500-2503; originally published online Oct 13, 2005;

TÉCNICAS ENDOVASCULARES

FIBRINOLISIS INTRAARTERIAL

TROMBECTOMÍA MECÁNICA

- **6-8 HORAS**
  CIRCULACIÓN ANTERIOR

- **24 HORAS**
  CIRCULACIÓN POSTERIOR

FIBRINOLISIS INTRAARTERIAL

TÉCNICA

Administración LOCAL o REGIONAL del fibrinolítico en el vaso ocluido

Angiografía cerebral completa:

- localización oclusión
- extensión del trombo
- territorios afectados
- colaterales

Cateterismo selectivo:

- catéter guía en vaso portador
- microcatéter hasta sitio de oclusión

Infusión del fibrinolítico:

- intratrombo
- proximal al trombo

FIBRINOLISIS INTRAARTERIAL

TÉCNICA

Agentes fibrinolíticos:

- rtPA
- r-pro-UK (requiere heparina)
- alteplase, TNK-tPA, ….

baja dosis heparina
(2000UI/bolo
+
500UI/h 4 horas)

Series angiográficas de control secuencialmente:

15-30-60….120min

Recanalización ***lo más rápida posible con la menor dosis de fibrinolítico*** *para limitar la extensión del infarto y reducir el riesgo de hemorragia*

FIBRINOLISIS INTRAARTERIAL

Intra-arterial Prourokinase for Acute Ischemic Stroke

JAMA, December 1, 1999—Vol 282, No. 21

The PROACT II Study: A Randomized Controlled Trial

n=180 pacientes
oclusión angiográfica ACM
6 horas
sin hemorragia ni infarto
mayor en CT

	RECANALIZACION	HIS	MORTALIDAD
r-pro-UK I.A. + HEPARINA (n=121)	**66%**	**10%**	**25%**
HEPARINA (n=59)	**18%**	**2%**	**27%**

Table 4. Secondary Clinical Outcomes at 90-Day Follow-up Assessment*

Outcome (90-Day Follow-up)*	r-proUK Group (n = 121), %†	Control (n = 59), %†	Absolute Difference, %	*P* Value
mRs ≤1	26	17	9	.16
Barthel index ≥90	41	32	9	.24
Barthel index ≥60	54	47	7	.39
NIHSS score ≤1	18	12	6	.30
NIHSS score ≥50% decrease	50	44	6	.46
Mortality‡	25	27	−2	.80

FIBRINOLISIS INTRAARTERIAL

LOCALIZACIÓN OCLUSIÓN

Índices de recanalización y resultados clínicos de trombolisis varían según **localización de la oclusión y técnica de recanalización**:

- en gral, oclusión ACM distal a lenticuloestriadas (M1 distal, M2)
  mejor que
  oclusión ACI en "T"
  mejor que
  ACI

- en oclusión cerebrovascular mayor, los índices de recanalización con trombolisis I.A. son superiores I.V.
  70% I.A.
  30% I.V.
  las diferencias son mayores cuanto > calibre del vaso (ACI> ACI distal T > ACM(M1)

Local Intra-Arterial Fibrinolysis in Acute Hemispheric Stroke: Effect of Occlusion Type and Fibrinolytic Agent on Recanalization Success and Neurological Outcome. *Cerebrovasc Dis 2003;15:258-263*

Trial Design and Reporting Standards for Intra-Arterial Cerebral Thrombolysis for Acute Ischemic Stroke
Randall T. Higashida and Anthony J. Furlan
Stroke 2003;34;e109-e137; originally published online Jul 17, 2003;

FIBRINOLISIS INTRAARTERIAL

LOCALIZACIÓN OCLUSIÓN

Los datos sugieren que los trombos en grandes vasos son relativamente resistentes a la fibrinolisis intravenosa, mientras que pueden responder favorablemente a la lisis intraarterial.

No hay estudios randomizados que comparen índices de recanalización y resultados clínicos entre F.I.A. y F.I.V.

Clinical and Vascular Outcome in Internal Carotid Artery Versus Middle Cerebral Artery Occlusions After Intravenous Tissue Plasminogen Activator
Italo Linfante, Rafael H. Llinas, Magdy Selim, Claudia Chaves, Sandeep Kumar, Robert A. Parker, Louis R. Caplan and Gottfried Schlaug
Stroke 2002;33;2066-2071

Site of Arterial Occlusion Identified by Transcranial Doppler Predicts the Response to Intravenous Thrombolysis for Stroke
Maher Saqqur, Ken Uchino, Andrew M. Demchuk, Carlos A. Molina, Zsolt Garami, Sergio Calleja, Naveed Akhtar, Finton O. Orouk, Abdul Salam, Ashfaq Shuaib, Andrei V. Alexandrov and for CLOTBUST Investigators
Stroke 2007;38;948-954; originally published online Feb 8, 2007;

FIBRINOLISIS INTRAARTERIAL

PREDICCIÓN

COMPLICACIONES

HEMORRÁGICAS

No hay datos definitivos

Algunos resultados sugieren que el riesgo de HIS tras fibrinolisis I.A.:
8,3% en territorio carotídeo
6,5% en territorio vertebrobasilar

No hay evidencia de que sea menor con fibrinolisis I.V.

FIBRINOLISIS INTRAARTERIAL

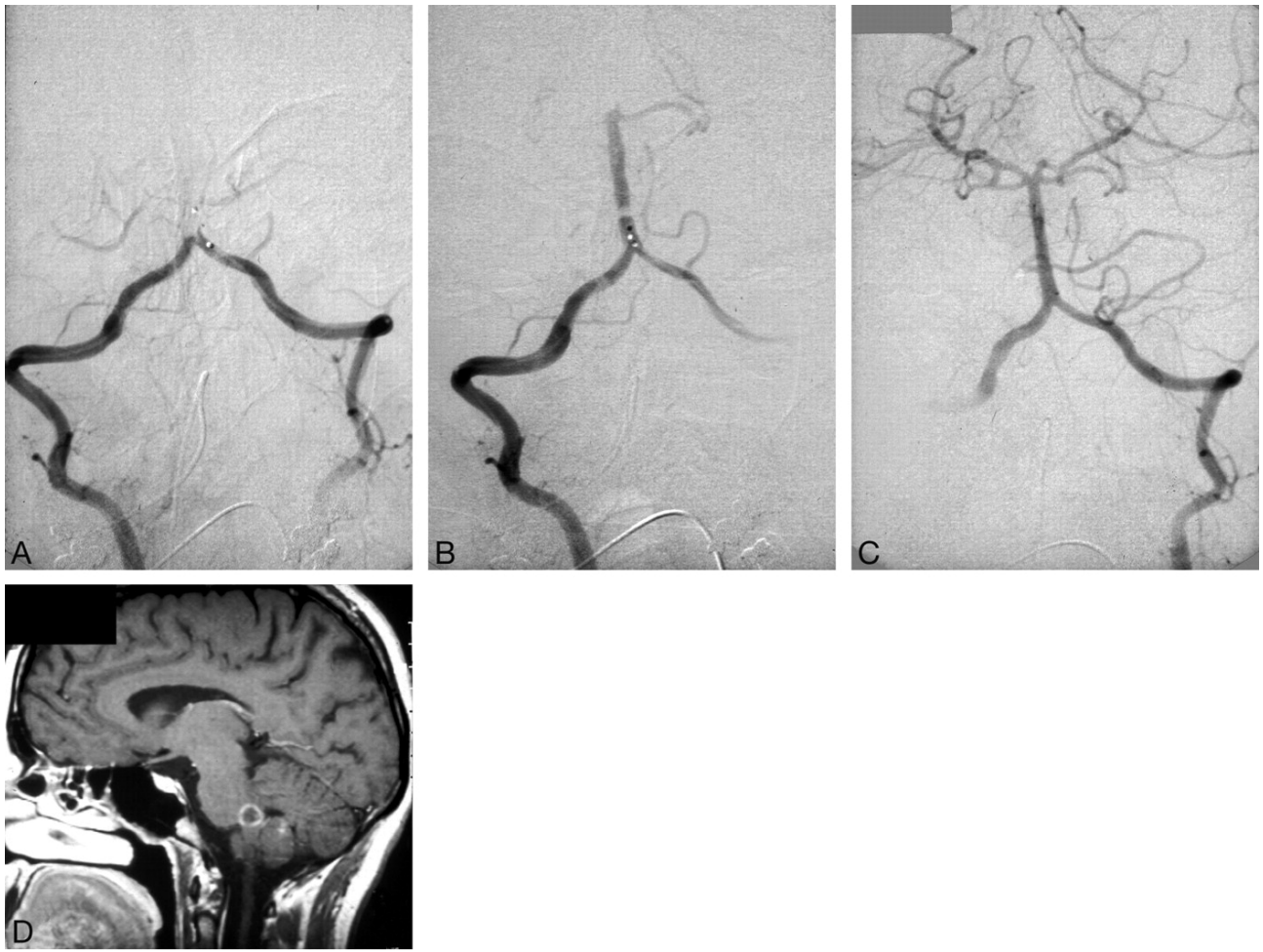

FIBRINOLISIS INTRAARTERIAL

LIMITACIONES

- necesidad de equipo especializado
- retraso en el tiempo de inicio del tratamiento
- complicaciones inherentes a la técnica

AGF cerebral---------- morbilidad 1,4%
mortalidad 0,5%
déficit neurológico permanente 0,06%

- REOCLUSIÓN ARTERIAL: 18%
- EMBOLIZACIÓN DISTAL: 16%

Impact of Arterial Reocclusion and Distal Fragmentation during Thrombolysis among Patients with Acute Ischemic Stroke

AJNR Am J Neuroradiol 29:253–58 | Feb 2008 |

FIBRINOLISIS INTRAARTERIAL

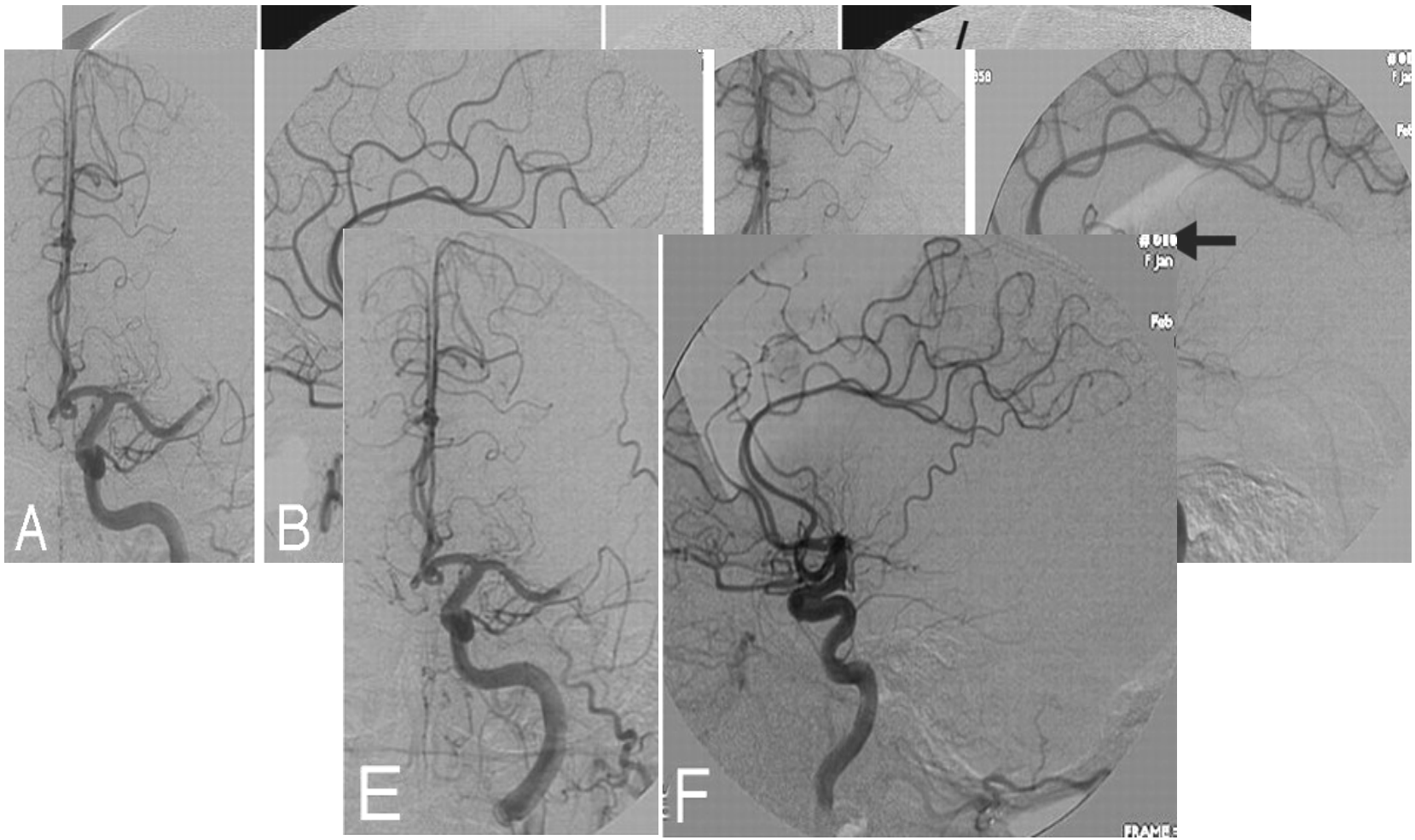

FIBRINOLISIS INTRAARTERIAL

VENTAJAS

- incremento de la ventana terapéutica de 3 a 6 horas (**mayor número de pacientes tratables**)
- incremento en la tasa de recanalización, especialmente en oclusión mayor
- mejoría de los resultados clínicos

FIBRINOLISIS COMBINADA I.V. + I.A.

Intravenous Versus Combined (Intravenous and Intra-Arterial) Thrombolysis in Acute Ischemic Stroke: A Transcranial Color-Coded Duplex Sonography-Guided Pilot Study
Lucka Sekoranja, Jaouad Loulidi, Hasan Yilmaz, Karl Lovblad, Philippe Temperli, Mario Comelli and Roman F. Sztajzel
Stroke 2006;37;1805-1809; originally published online Jun 8, 2006;

n= 33
oclusión ACM
3 horas

Comparison of combined venous and arterial thrombolysis with primary arterial therapy using recombinant tissue plasminogen activator in acute ischemic stroke.
J Stroke Cerebrovasc Dis. 2008 May-Jun;17(3):121-8

0,9mg/kg rtPA IV

Is Intra-Arterial Thrombolysis Safe After Full-Dose Intravenous Recombinant Tissue Plasminogen Activator for Acute Ischemic Stroke?
Hashem M. Shaltoni, Karen C. Albright, Nicole R. Gonzales, Raymond U. Weir, Aslam M. Khaja, Rebecca M. Sugg, Morgan S. Campbell, III, Edwin D. Cacayorin, James C. Grotta and Elizabeth A. Noser
Stroke 2007;38;80-84; originally published online Nov 22, 2006;

ora

TIBI a 30 minutos

FIBRINOLISIS I.A.

SI

RECANALIZACIÓN PRECOZ
modificación TIBI>=1, 30min

NO

FIBRINOLISIS COMBINADA I.V. + I.A.

- parece una técnica **segura**
(*seguridad referida a HIS o transformación hemorrágica con deterioro clínico >2 ptos en NIHSS, o complicación sistémica hemorrágica)
y **eficaz**
(aumento de la tasa de recanalización)

- combina la ventaja del tratamiento de rápida instauración intravenoso con la mayor tasa de recanalización de la vía intraarterial

- en ausencia de recanalización precoz tras rtPA i.v., la asociación de tratamiento intraarterial mejora los resultados clínicos

TROMBECTOMÍA MECÁNICA

DISPOSITIVOS

"Rescate endovas

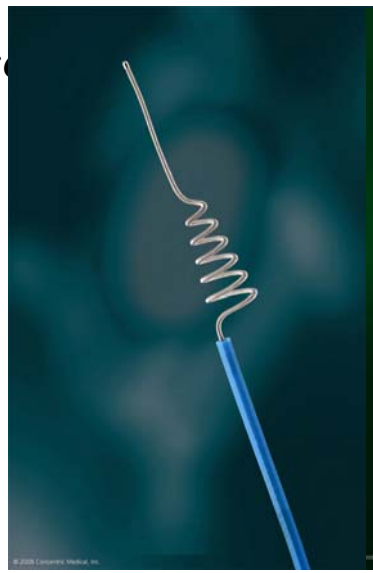

PENUMBRA

MERCI





TROMBECTOMÍA MECÁNICA

TÉCNICA

TROMBECTOMÍA MECÁNICA

TÉCNICA

TÉCNICAS ENDOVASCULARES

TROMBECTOMÍA MECÁNICA

Safety and Efficacy of Mechanical Embolectomy in Acute Ischemic Stroke: Results of the MERCI Trial

Wade S. Smith, Gene Sung, Sidney Starkman, Jeffrey L. Saver, Chelsea S. Kidwell, Y.Pierre Gobin, Helmi L. Lutsep, Gary M. Nesbit, Thomas Grobelny, Marilyn M. Rymer, Isaac E. Silverman, Randall T. Higashida, Ronald F. Budzik, Michael P. Marks and for the MERCI Trial Investigators

Stroke 2005;36;1432-1438; originally published online Jun 16, 2005;

recanalización 48%
complicaciones procedimiento clínicamente significativas 7,1%
HIS 7,8%
mejoría clínica a 90 días (mrs< =2) 46% (10% sin recanaliz.)
mortalidad 32% (54% sin recanaliz.)

TABLE 2. Neurological Outcomes a

Assessment	Overall				
Favorable outcome, 30 d					
Modified Rankin score*	22.6	[illegible]	[illegible]	[illegible]	[illegible]
NIHSS score†	34.1	54.0	15.9	3.39 (1.88–6.09)	<0.0001
Favorable outcome, 90 d					
Modified Rankin score*	27.7	46.0	10.4	4.41 (2.08–9.33)	<0.0001
NIHSS score†	32.4	50.0	17.5	2.85 (1.52–5.35)	0.0007
Mortality at 30 days	37.1	23.9	49.3	0.48 (0.30–0.79)	0.0028
Mortality at 90 days	43.5	31.8	54.2	0.59 (0.39–0.89)	0.0101
Death, MI, new stroke, 30 d	40.0	29.9	49.3	0.61 (0.39–0.93)	0.0247

*Rankin ≤2.
†NIHSS score improvement from baseline by ≥10 points.

F.I.A. asociada si fallo recanalización o para tratar embolismo distal

TABLE 1. Patient Demographics, Baseline Stroke Score, Site of Vascular Occlusion, and Primary Outcomes

	7.0±15.5
	46
	0.1±6.6
	19
	14
Middle cerebral artery	57
Vertebral artery	1
Basilar artery	9
Revascularization (%, 95% CI)	48 (40–57)
Procedural complications (%, 95% CI)	
All	13 (7.3–18)
Clinically significant	7.1 (2.9–11)
Symptom onset to groin puncture, mean hr±SD	4.3±1.7
Procedure duration, mean hr±SD, (range)	2.1±1.0 (0.3–5.9)
Attempts to remove clot (n±SD)	2.9±1.5
Enrolled <3 hours of symptom onset, no. (%)	38 (27)

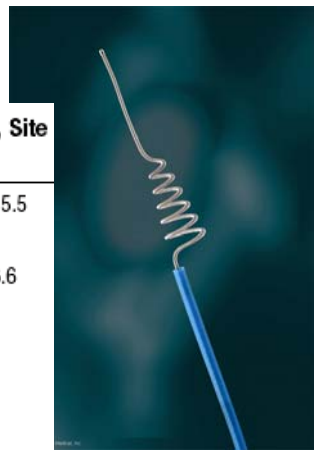

TÉCNICAS ENDOVASCULARES

TROMBECTOMÍA MECÁNICA

Mechanical Thrombectomy for Acute Ischemic Stroke: Final Results of the Multi MERCI Trial

Wade S. Smith, Gene Sung, Jeffrey Saver, Ronald Budzik, Gary Duckwiler, David S. Liebeskind, Helmi L. Lutsep, Marilyn M. Rymer, Randall T. Higashida, Sidney Starkman, Y. Pierre Gobin and for the Multi MERCI Investigators

Stroke 2008;39;1205-1212; originally published online Feb 28, 2008;



MultiMERCI

recanalización 57,3% (69,5% asociada a rtPA i.a.)
complicaciones procedimiento clínicamente significativas 5,5%
HIS 9,8%
resultados clínicos favorables (mRS<=2) 36%
mortalidad 34%

MERCI

recanalización 48%
complicaciones procedimiento clínicamente significativas 7,1%
HIS 7,8%
mejoría clínica a 90 días (mrs< =2) 46% (10% sin recanaliz.)
mortalidad 32% (54% sin recanaliz.)

Table 1. P… Site of vascu…	
No. of patients	
Age, mean±SD,	
Female, %	
Baseline NIHSS,	
Baseline mRS=0	86%
Baseline mRS, mean±SD	0.34±0.95
Site of vascular occlusion, % (n)	
ICA/ICA ter…	
Middle cerebr…	
Vertebral/basi…	

Table 2. Major Outcomes	
	55 (47–63)
	68 (61–75)
	4.3 (3.2–5.3)
	1.6 (1.2–2.3)
	2.9±1.6
	29
	9.8 (5.2–14.3)
Clinically significant procedure complication, % (95% CI)	5.5 (2.0–9.0)
Device-related serious adverse event rate, %	2.4 (0.1–4.8)
	36 (29–44)
	26 (19–33)
	34 (26–41)
	9.8 (5.2–14.3)
	2.4 (0.1–4.8)

TROMBECTOMÍA MECÁNICA

The Penumbra System: A Mechanical Device for the Treatment of Acute Stroke due to Thromboembolism AJNR Am J Neuroradiol 29:1409–13 | Aug 2008

- n=23, 20 tratados
- NIHSS>20---------- 11(45%)
- >3 horas evolución--------- 10 (50%)
- <3horas---------- 10
  - 6 refractarios a rtPA i.v.
  - 4 no-subsidiarios de rtPA
- localización oclusión:
  - 7 ACI
  - 5 ACM
  - 9 basilar
- NIHSS>20 y/o oclusión basilar--- 14(70%)
- 9 pac. TEM(PS) + F.I.A.

Recanalización: 100% de tratados
HIC= 8 (7 PS + F.I.A.)
HIS = 2

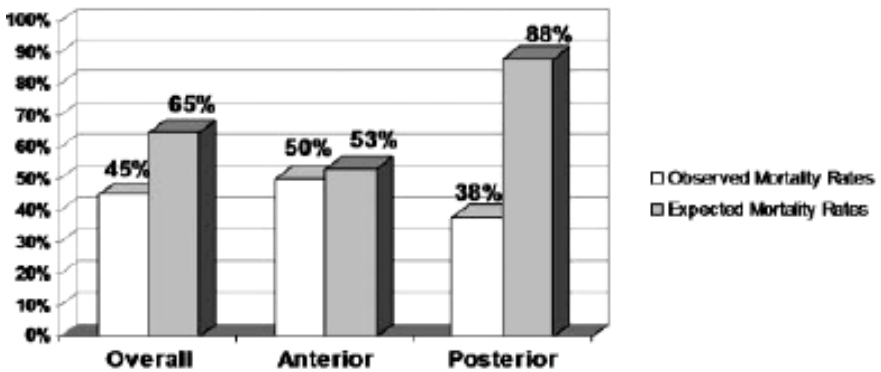

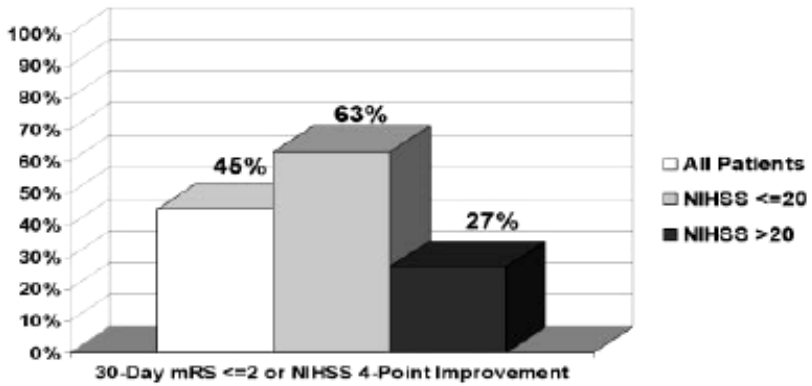

TROMBECTOMÍA MECÁNICA

LIMITACIONES

- necesidad de equipo especializado
- retraso en el tiempo de inicio del tratamiento
- complicaciones inherentes a la técnica
  - **reoclusión arterial**
  - **embolización distal**
  - **relativas al dispositivo:**
    - perforación vascular
    - disección arterial

TÉCNICAS ENDOVASCULARES

TROMBECTOMÍA MECÁNICA

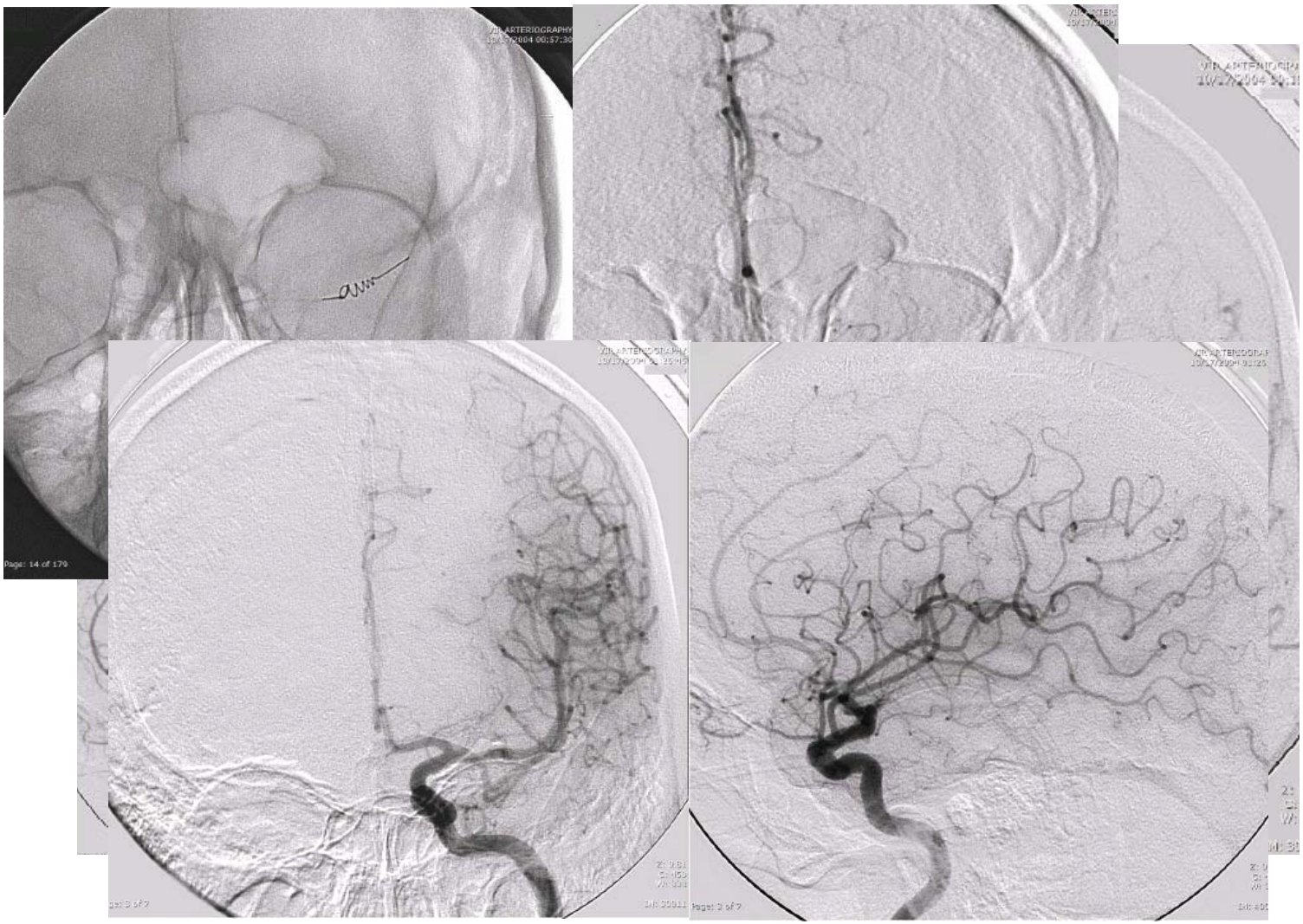

TÉCNICAS ENDOVASCULARES

TROMBECTOMÍA MECÁNICA

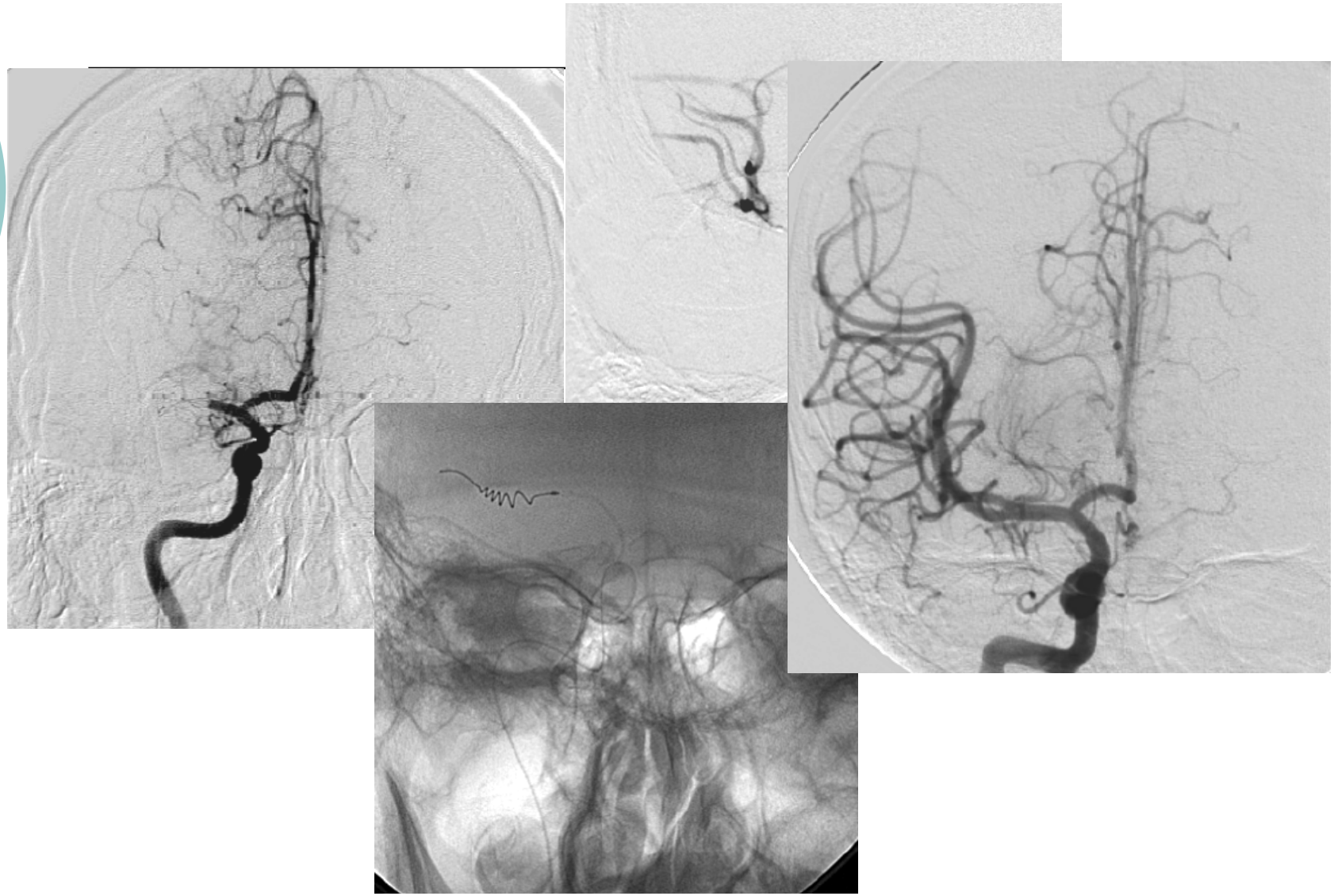

TÉCNICAS ENDOVASCULARES

TROMBECTOMÍA MECÁNICA

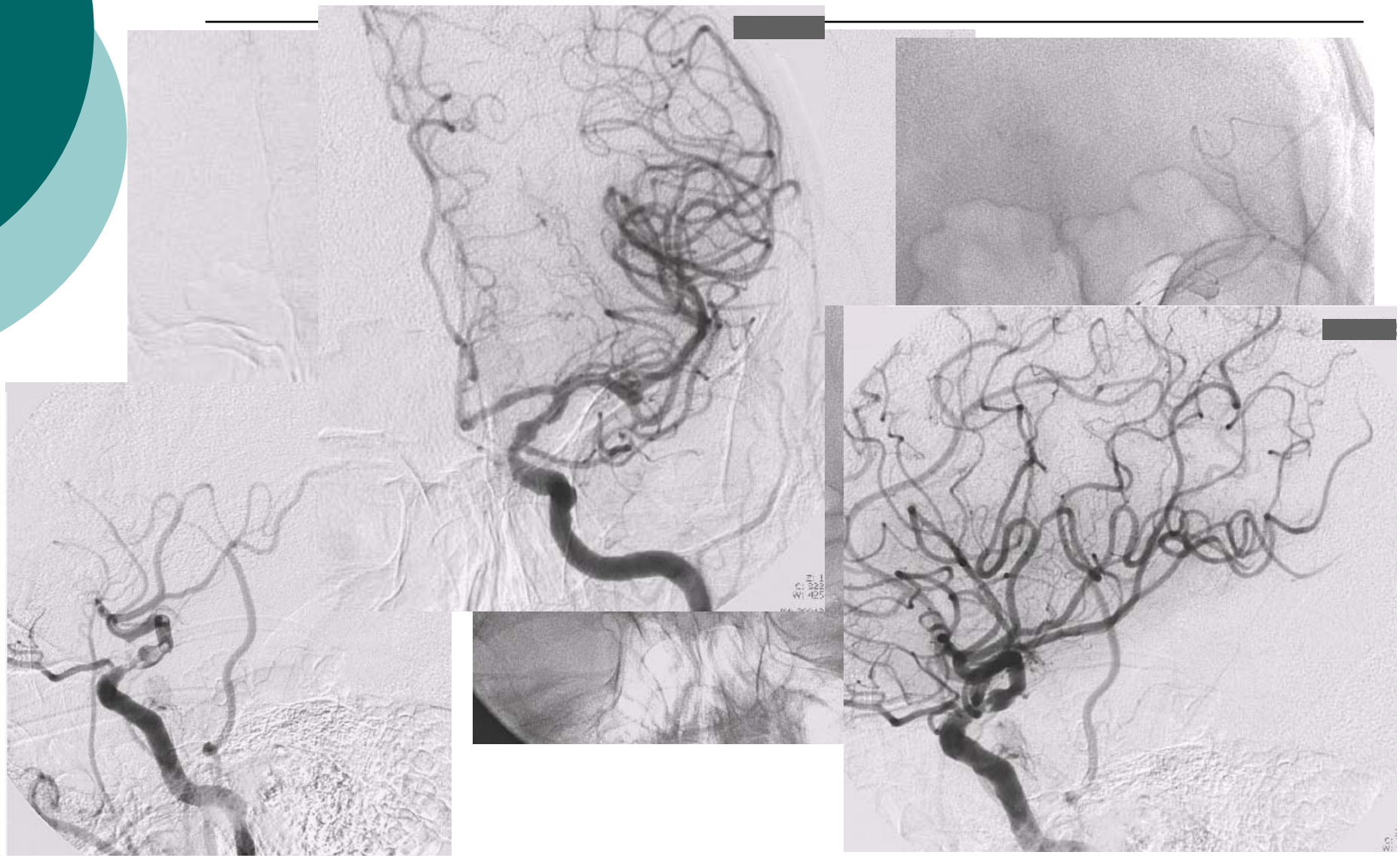

TÉCNICAS ENDOVASCULARES

TROMBECTOMÍA MECÁNICA

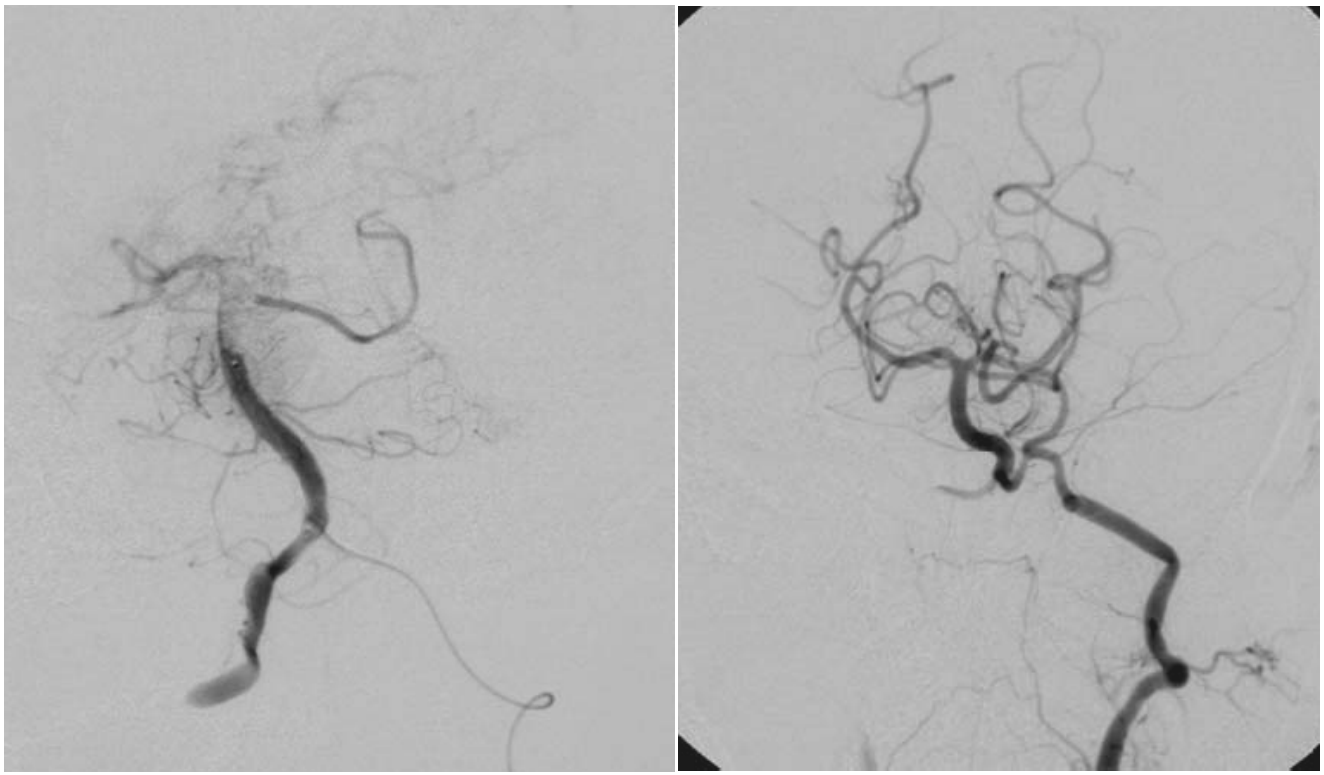

TÉCNICAS ENDOVASCULARES

TROMBECTOMÍA MECÁNICA

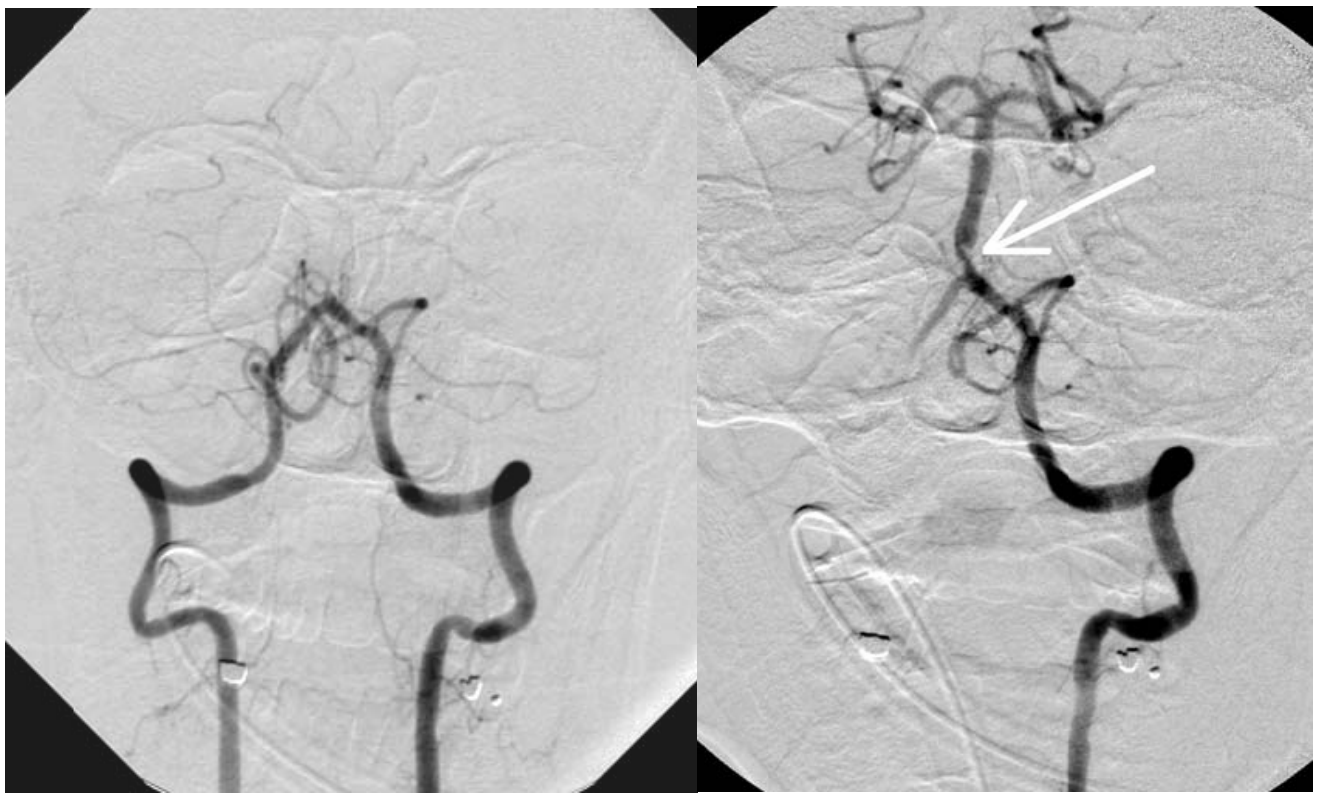

TROMBECTOMÍA MECÁNICA

¿CANDIDATOS A TEM?

- **alternativa a rtPA i.v. (NO-INDICADA) :**
  - ✓ **>3 horas**
  - ✓ **fibrinolíticos contraindicados**
    - **anticoagulantes orales**
    - **cirugía reciente**
    - **IAM o ictus reciente**
    - **postparto**

❖ Ictus severo-moderado:
NIHSS >=8
oclusión grandes vasos

† fallo rtPA i.v.

VENTAJAS

- **8 horas circulación anterior**
- **24 horas circulación posterior**
- **mejores resultados en oclusión de grandes vasos**

ANGIOPLASTIA Y STENT

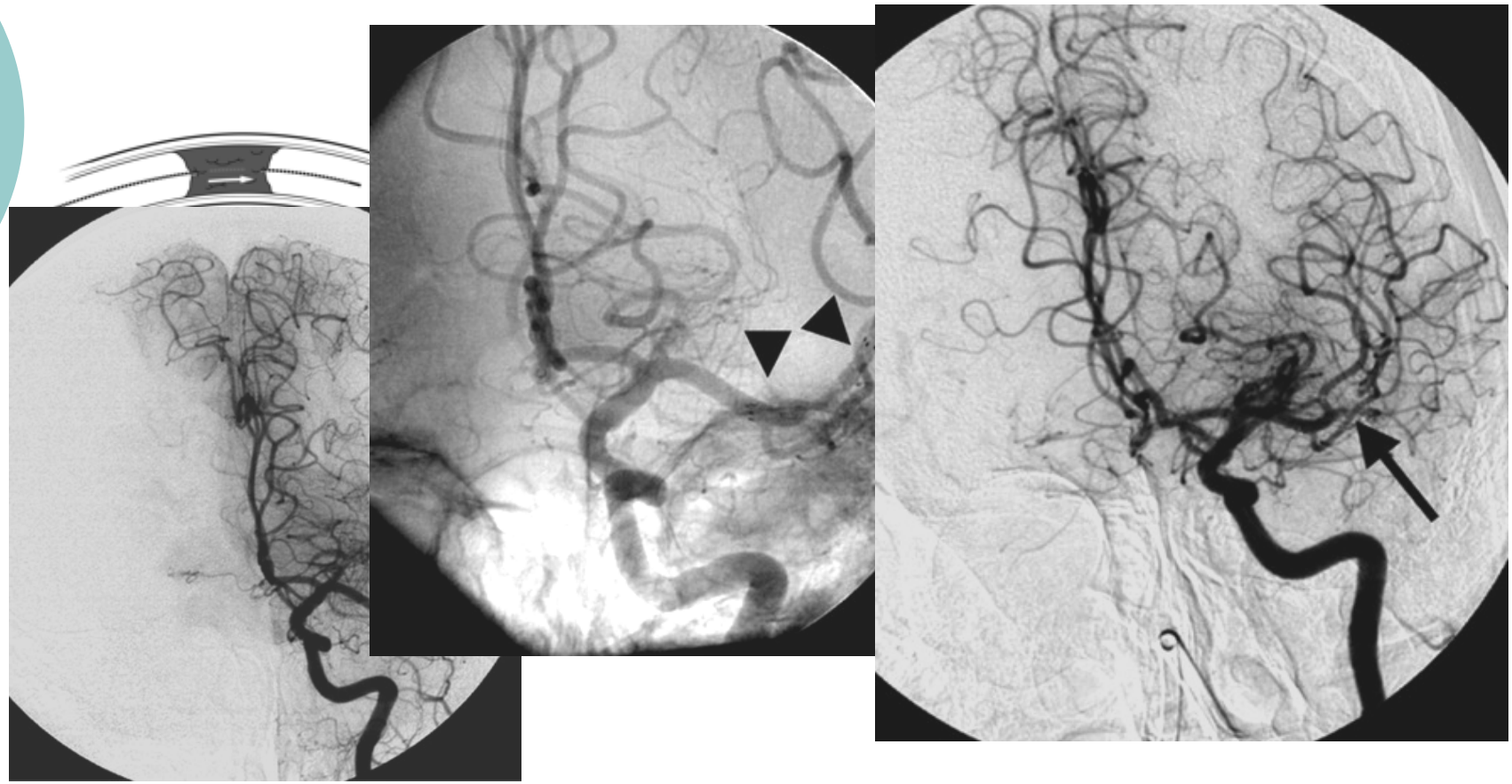

Self-Expanding Stents for Recanalization of Acute Cerebrovascular Occlusions

Levy | AJNR 28 | May 2007

SITUACIÓN ACTUAL

American Stroke

Intravenous rt n dose 90 mg) is
recommended o may be treated
Intra-arterial t n for treatment
of selected patie oke of <6 hours'
duration due to occlusions of the MCA and who are not

MR RESCUE

IMS-III trials

Although the MERCI device is a reasonable intervention for extraction of intra-arterial thrombi in carefully selected patients, the panel also recognizes that the utility of the device in improving outcomes after stroke is unclear (Class IIb, Level of Evidence B). *This recommendation has been added since the previous guideline.* The panel also recommends that the device be studied in additional clinical trials that will define its role in the emergency management of stroke. *This is the first time that a panel has made a recommendation about endovascular treatment of patients with acute ischemic stroke.*

TERAPIAS REVASCULARIZACIÓN

FUTURO.....

TÉCNICAS DE IMAGEN EN ICTUS

SELECCIÓN DE PACIENTES

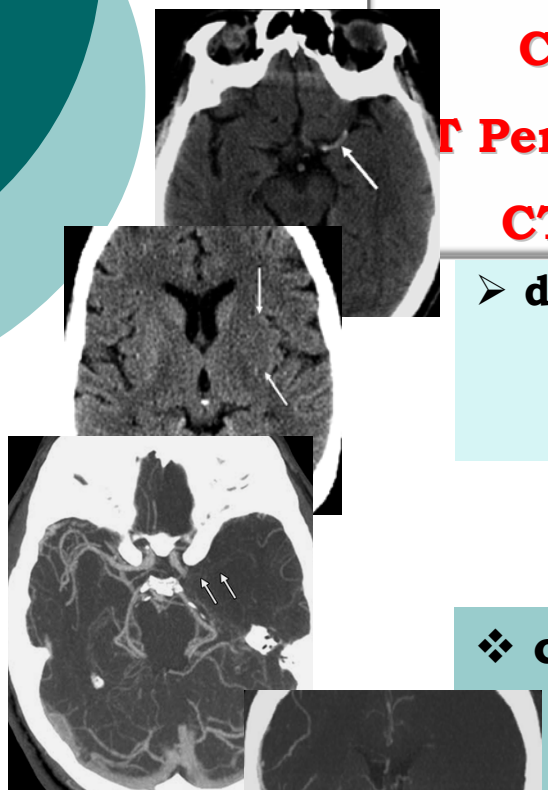

CT

T Perfusión

CTA

MR (FLAIR,GRE)

DWI, PWI

MRA

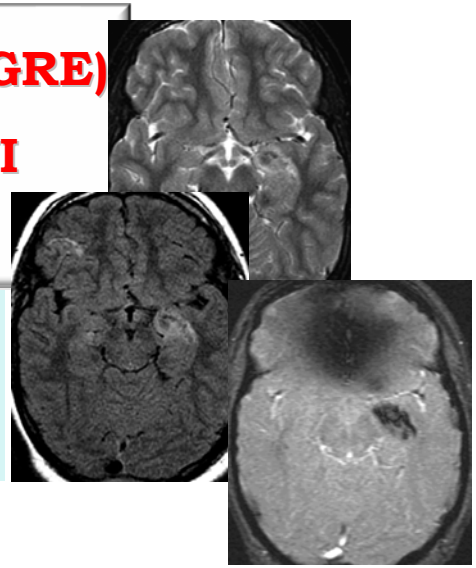

- **diagnóstico precoz**:
  - ✓ signos precoces de isquemia
  - ✓ hemorragia
  - ✓ imitadores: tumor, infección

- **circulación extra/intracraneal**:
  - ✓ localización y extensión de oclusión
  - ✓ posible etiopatogenia (disección, aterotrombosis,…)

CLINICAL APPLICATIONS OF VASCULAR IMAGING

State-of-the-Art Imaging of Acute Stroke[1]

RadioGraphics 2006; 26:S75–S95

TÉCNICAS DE IMAGEN EN ICTUS

SELECCIÓN DE PACIENTES

† Parénquima hipoperfundido todavía viable y potencialmente salvable

PENUMBRA ISQUÉMICA

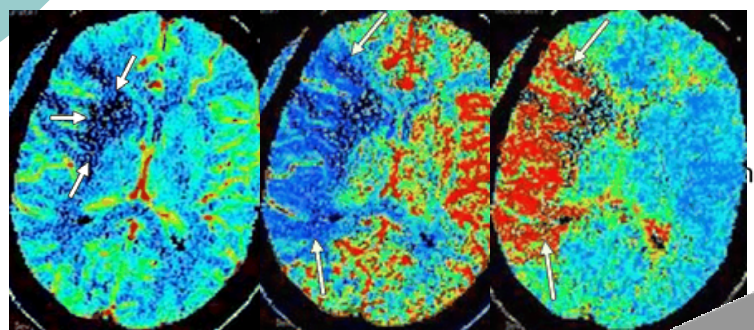

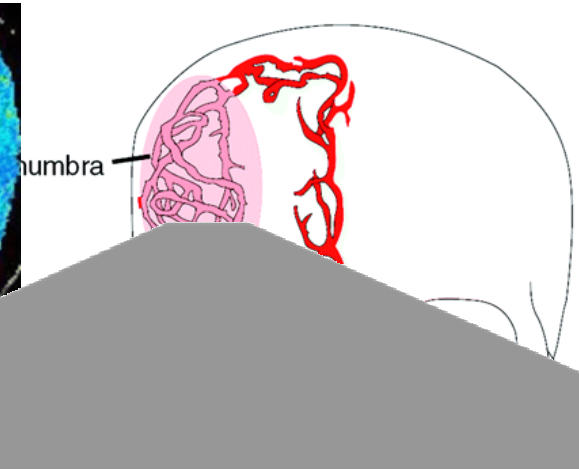

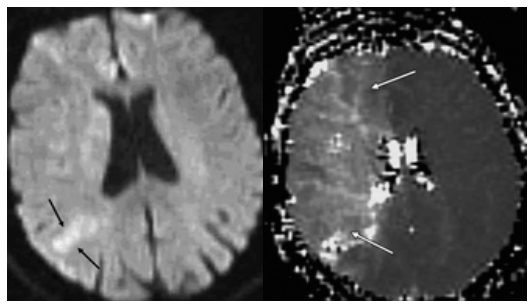

TERAPIAS REVASCULARIZACIÓN

Imaging-Guided Acute Ischemic Stroke Therapy: From "Time Is Brain" to "Physiology Is Brain"
AJNR Am J Neuroradiol 27:728–35 | Apr 2006

Acute Stroke Imaging Research Roadmap
AJNR Am J Neuroradiol 29:E23–E30 | May 2008

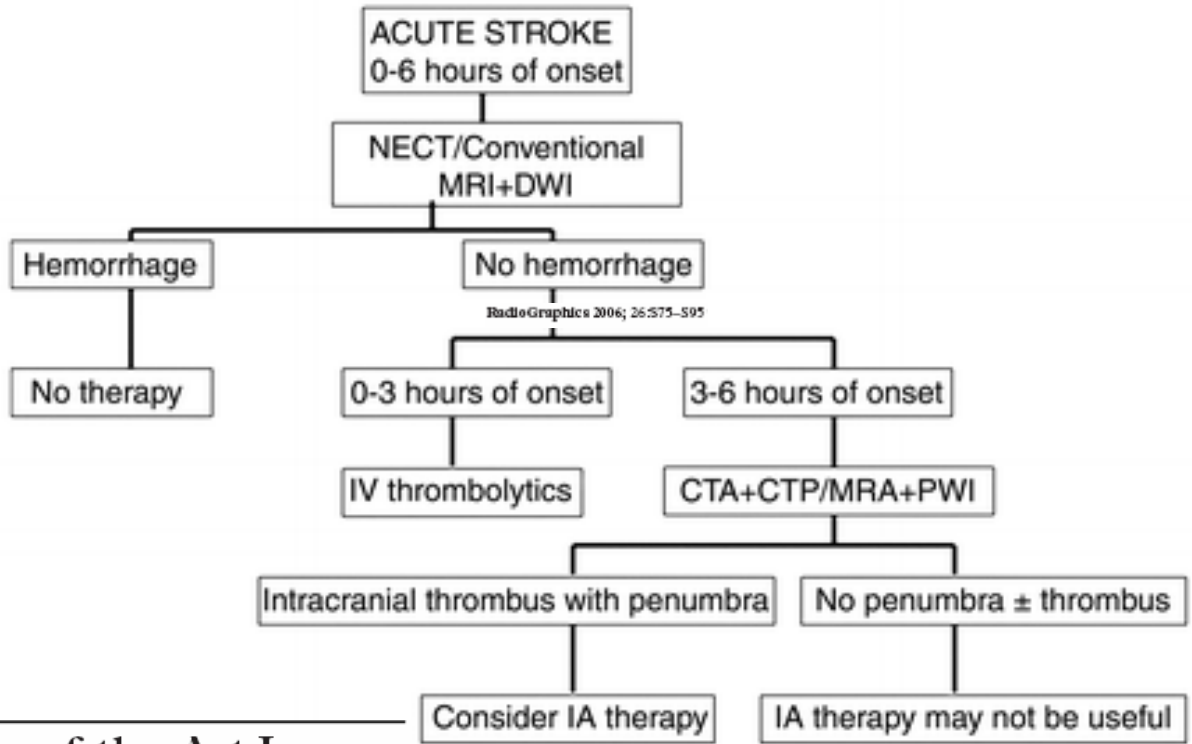

RadioGraphics

State-of-the-Art Imaging of Acute Stroke[1]

CME FEATURE

See accompanying test at http://www.rsna.org/education/rg_cme.html

Ashok Srinivasan, MD • Mayank Goyal, MD • Faisal Al Azri, MD
Cheemun Lum, MD

Stroke is a leading cause of mortality and morbidity in the developed

TÉCNICAS DE IMAGEN EN ICTUS

SELECCIÓN DE PACIENTES

- **dia**
  - ✓
  - ✓
  - ✓

- **circulac**
  - ✓ local
  - ✓ posib
    ate

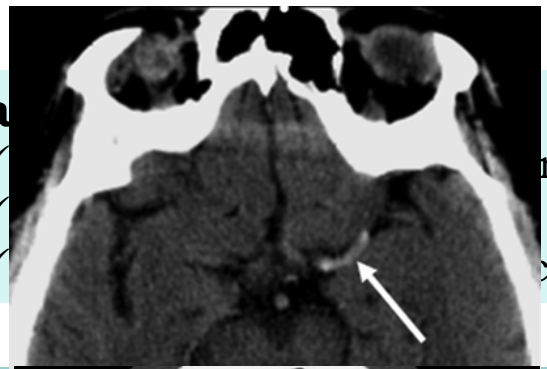

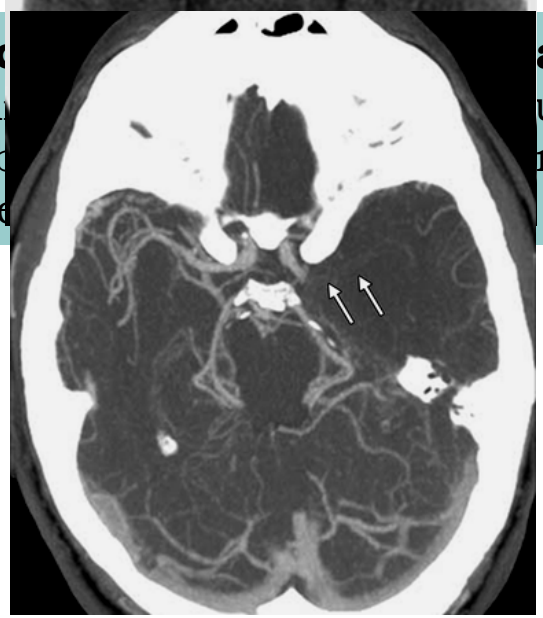

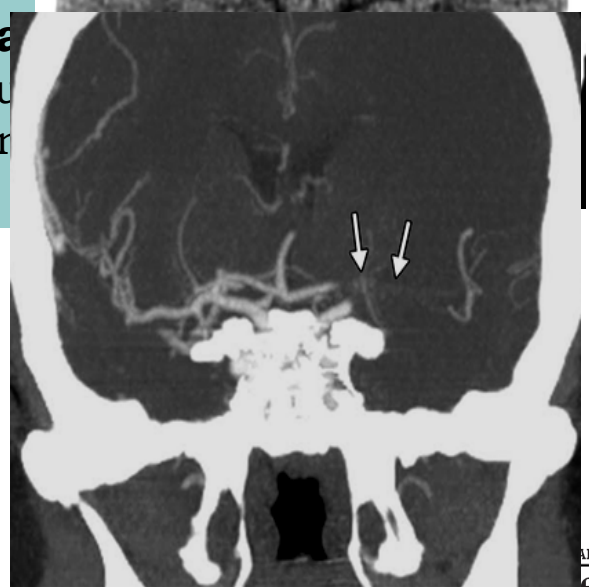

AR IMAGING S75
State-of-the-Art Imaging of Acute Stroke[1]
RadioGraphics 2006; 26:S75–S95

CTP

PENUMBRA
↑ MTT
CBF ↓ pero >60%
CBV N o ↑
O

MTT ↑
CBF ↓↓ >30%
CBV ↓ pero >60%

INFARTO

↑ MTT
↓↓↓ CBF (<30%)
↓↓↓ CBV (<40%)

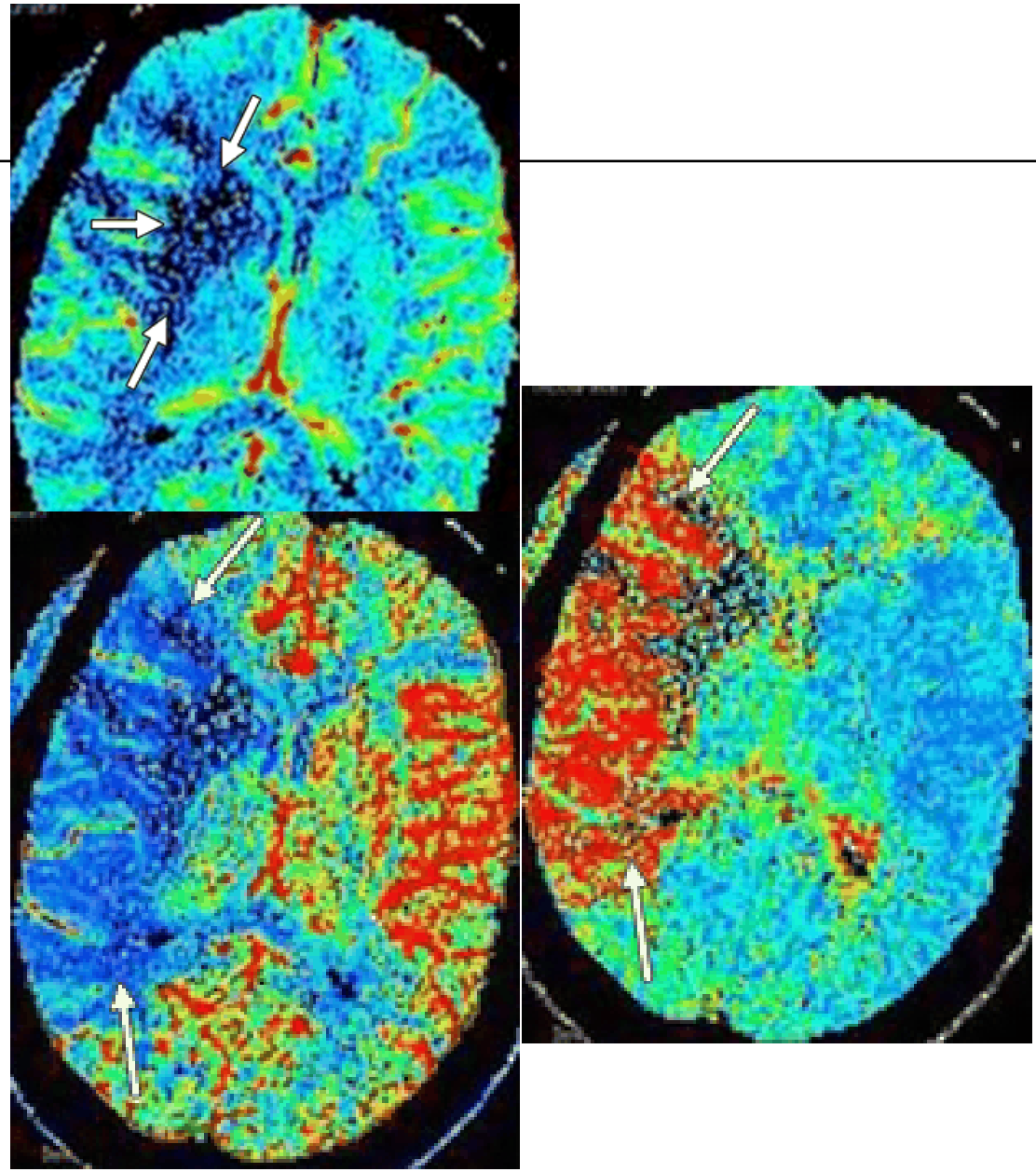

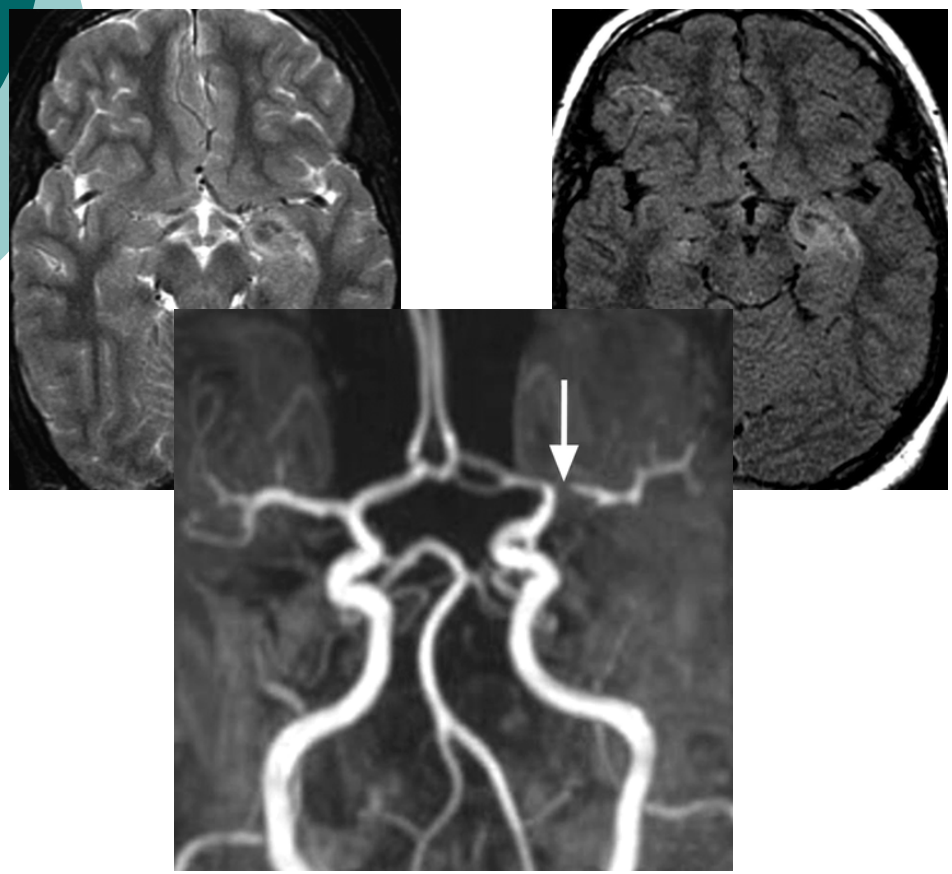

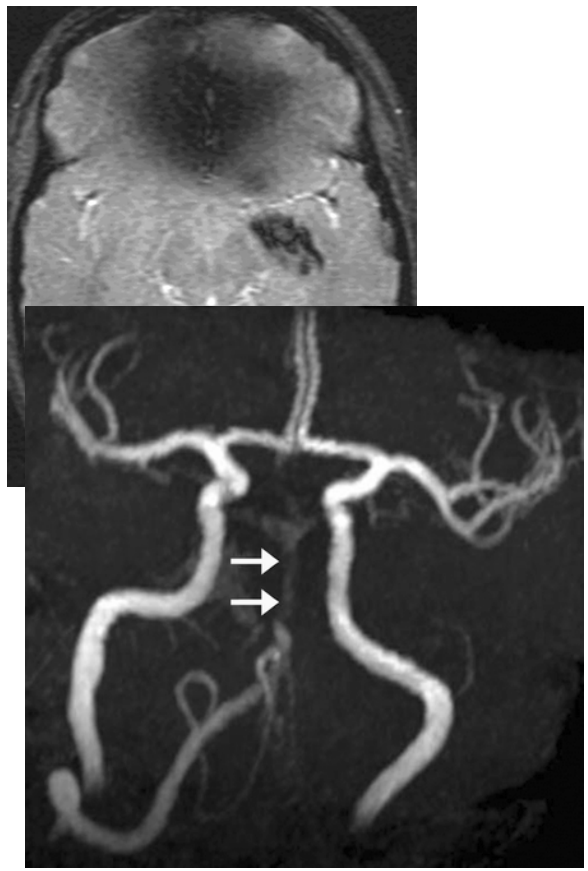

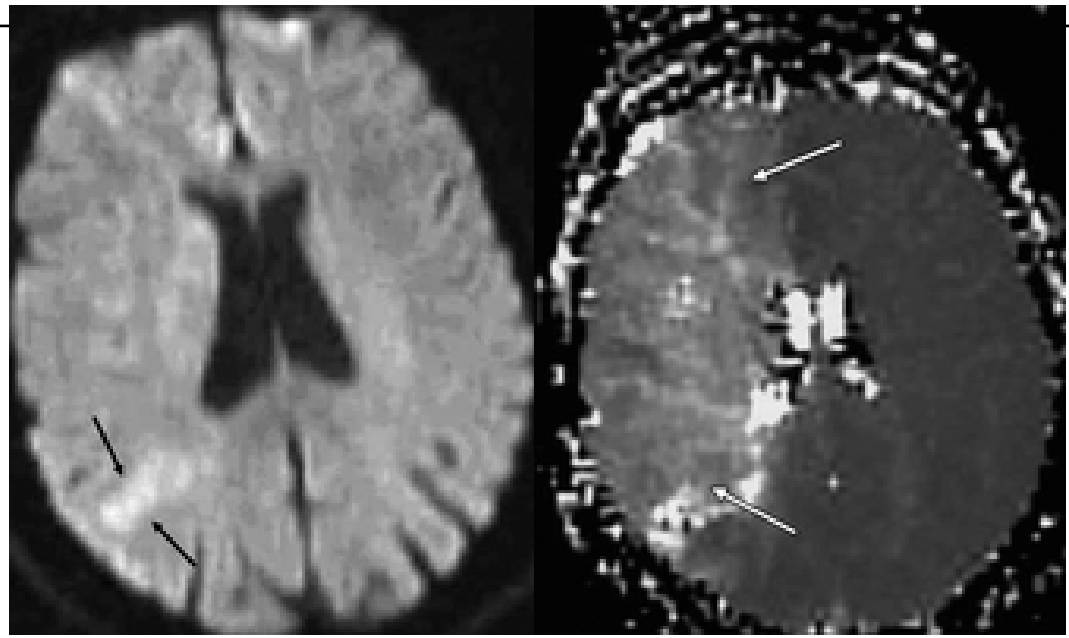

Imaging-Guided Acute Ischemic Stroke Therapy: From "Time Is Brain" to "Physiology Is Brain"

SUMMARY: The number of potential patients who are actually treated for acute ischemic stroke is disappointingly low, and effective treatments are making a minor impact on this major public health problem. Imaging is not regularly used to identify the ischemic penumbra, a key concept in stroke physiology, though it is capable of doing so in a clinically relevant manner. Evidence is accumulating that identification of the ischemic penumbra and making treatment decisions on the basis of its presence provide substantial benefit to patient outcomes. Moreover, the same studies suggest that an unexpectedly large proportion of patients are suitable for therapy well past the traditional time windows because of the existence of a substantial ischemic penumbra. Modern MR imaging and CT systems, now widely available, are capable of answering the most relevant physiologic questions in acute ischemic stroke. This capability presents new opportunities and responsibilities to neuroradiologists to make appropriate imaging readily available and to have the imaging data rapidly processed and interpreted. In this article, acute ischemic stroke therapy, including the role of imaging in current [illegible] and an evidence-based alternative to contemporary acute ischemic stroke therapy is suggested.

AJNR Am J Neuroradiol 27:728–35 | Apr 2006 |